

Labs 9 - 12

Bone Physiology and Anatomy and Skeletal System

Please refer to the bone list for
markings to learn

TODAY through 1/28

In the next 3 lab periods:

- Learn to identify all the bones and markings on your "bone list"
- Do all exercises Laboratory 9 - 12

Today: Please start by labeling the skeleton drawing with names of all bones - as you compare drawing to real skeleton. Skip Ossification and Activity 4 in Lab 9 for now (we'll do it on Tuesday after we talk about it in class).

Classification of Bones

206 bones in the adult

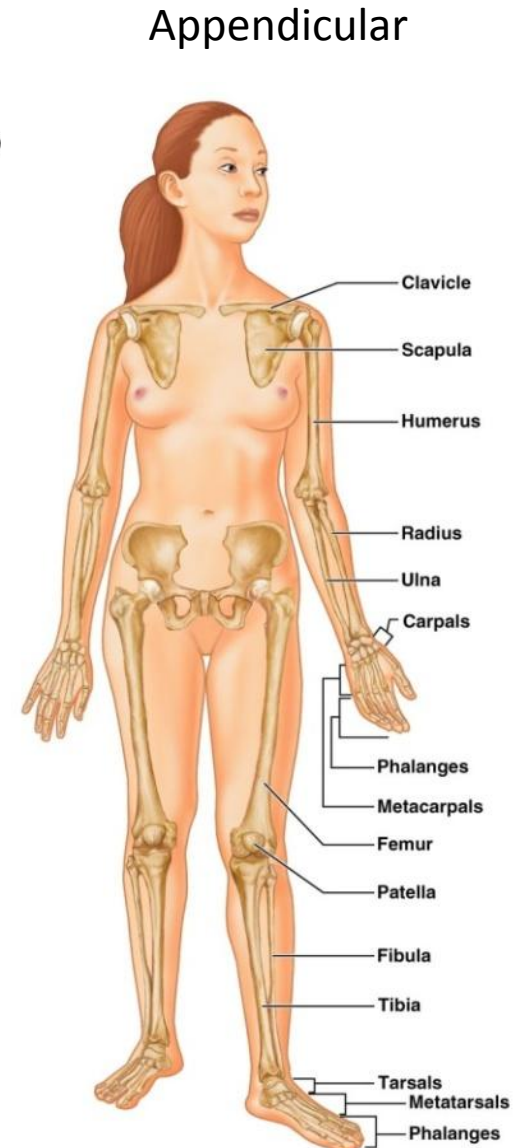
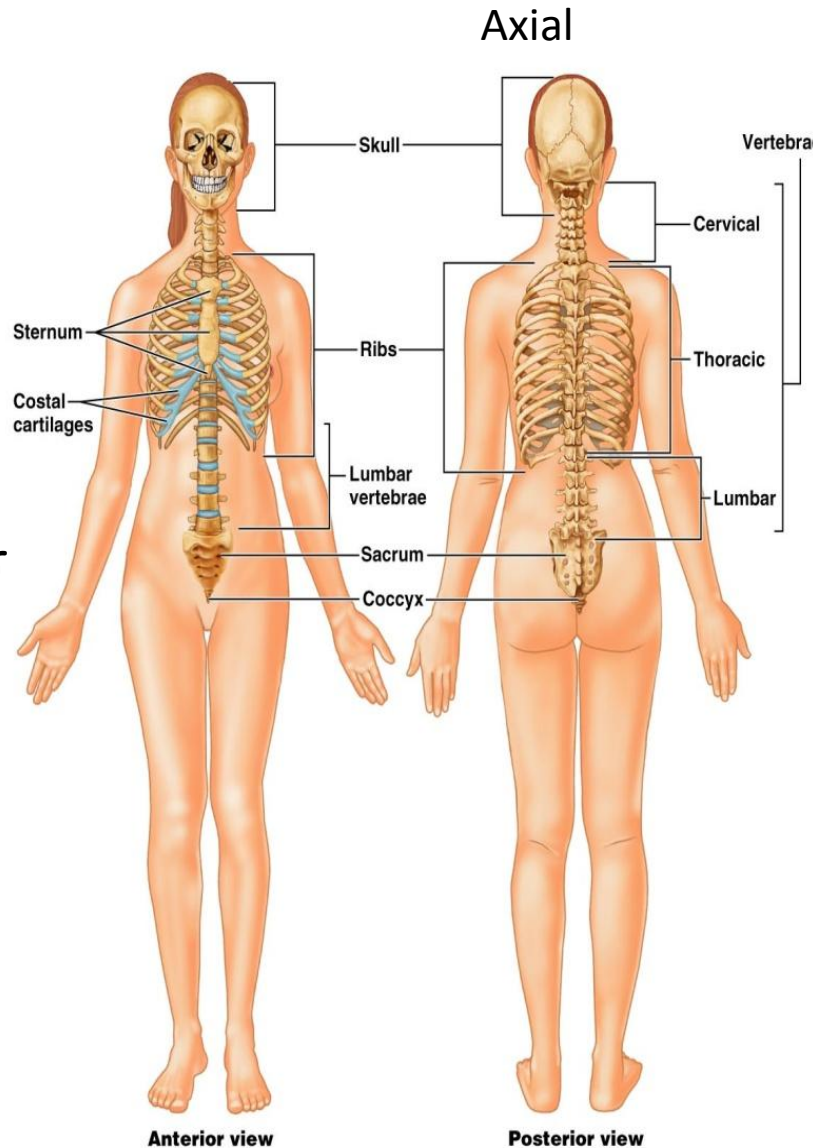
Axial - long axis of the body (skull, vertebral column and rib cage)
Lab 9 and 10

Appendicular - upper and lower limbs and limb girdles (hip and shoulders) Lab 11

Shapes: Long, Short, Flat or irregular

Types:

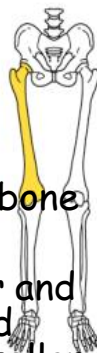- Spongy (cancellous)
- Compact (lamellar, haversian)



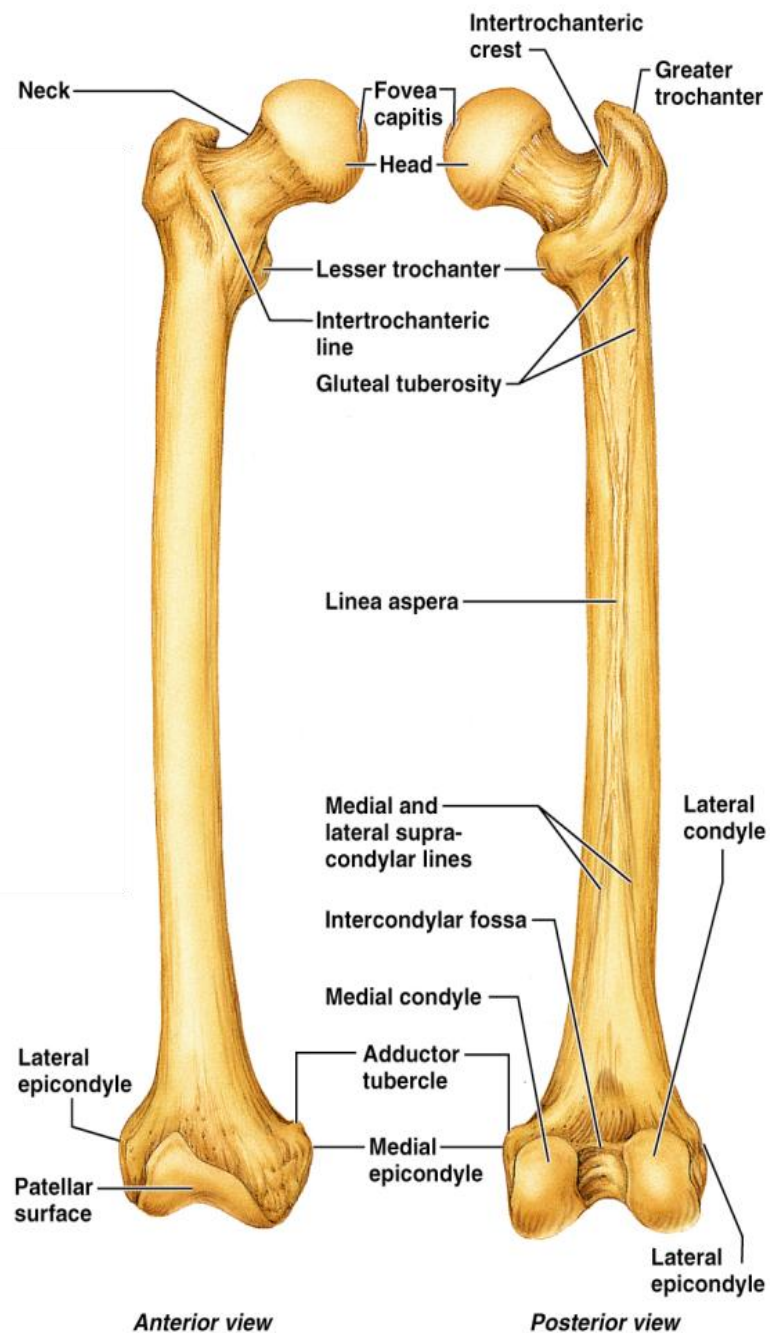
Bone Markings

Bulges, depressions, and holes that serve as sites of attachment for muscles, ligaments, and tendons, joint surfaces, conduits for blood vessels and nerves.

- Muscle/Ligament attachment sites
 - Tubercle - small rounded projection
 - Epicondyle - raised area above a condyle
 - Spine - sharp, slender projection
 - Process - any bony prominence
 - Tuberosity - rounded projection
 - Crest - narrow, prominent ridge of bone
 - Trochanter - large, blunt, irregular surface
 - Line - narrow ridge of bone
- Form Joints
 - Head - bony expansion on a narrow neck
 - Facet - smooth, nearly flat articular surface
 - Condyle - rounded articular projection
 - Ramus - armlike bar of bone
- Depressions (blood vessels and nerves to pass)
 - Sinus - cavity within a bone
 - Fossa - shallow, basin-like depression
 - Groove - furrow
 - Fissure - narrow, slit-like opening
 - Foramen - round or oval opening through a bone



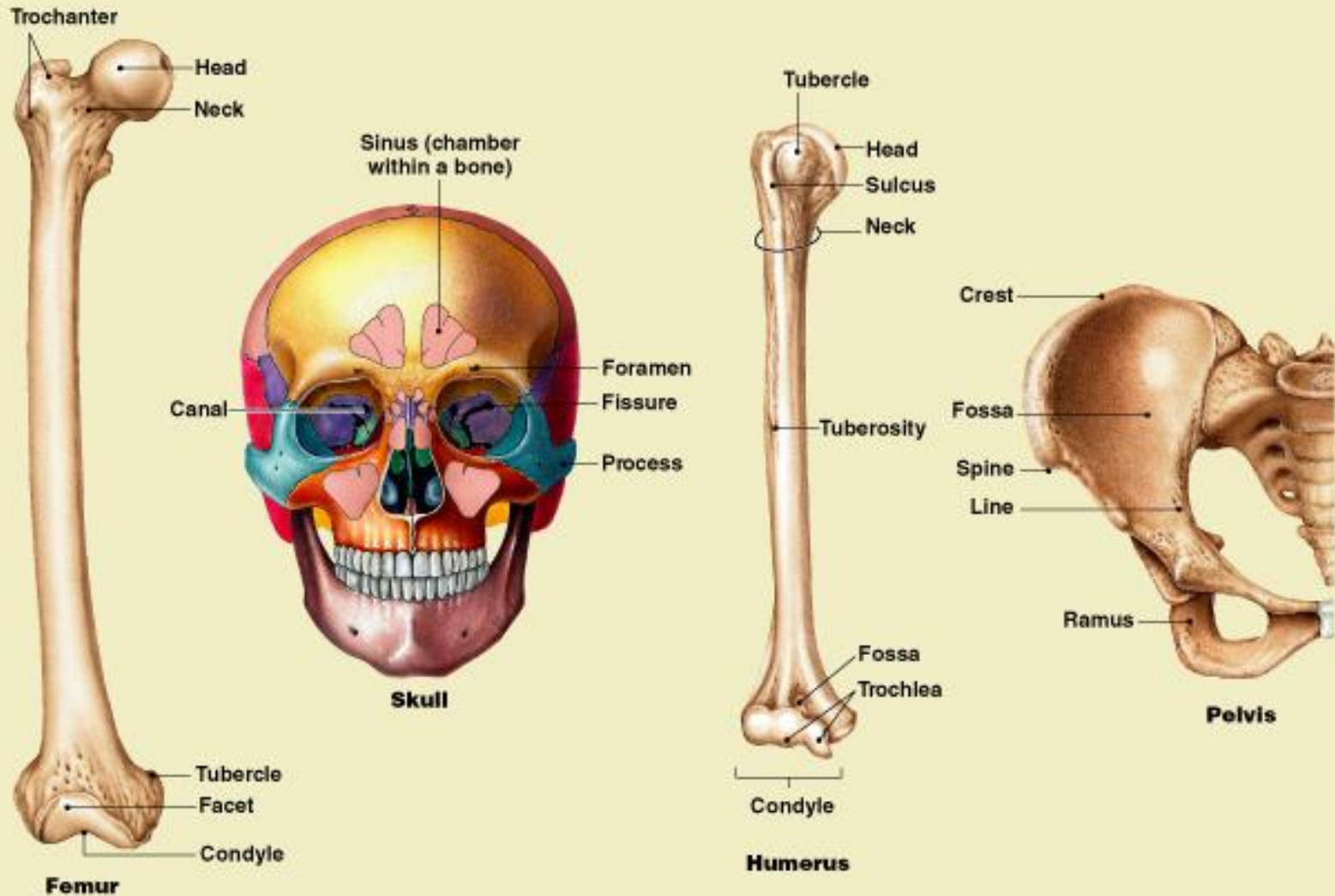
Major markings for femur include the head, greater and lesser trochanters, gluteal tuberosity, lateral and medial condyles and epicondyles, linea aspera, patellar surface, and the intercondylar notch



(b) Femur

Bone Markings

TABLE 6-1 An Introduction to Bone Surface Features



Growth in Length of Long Bone

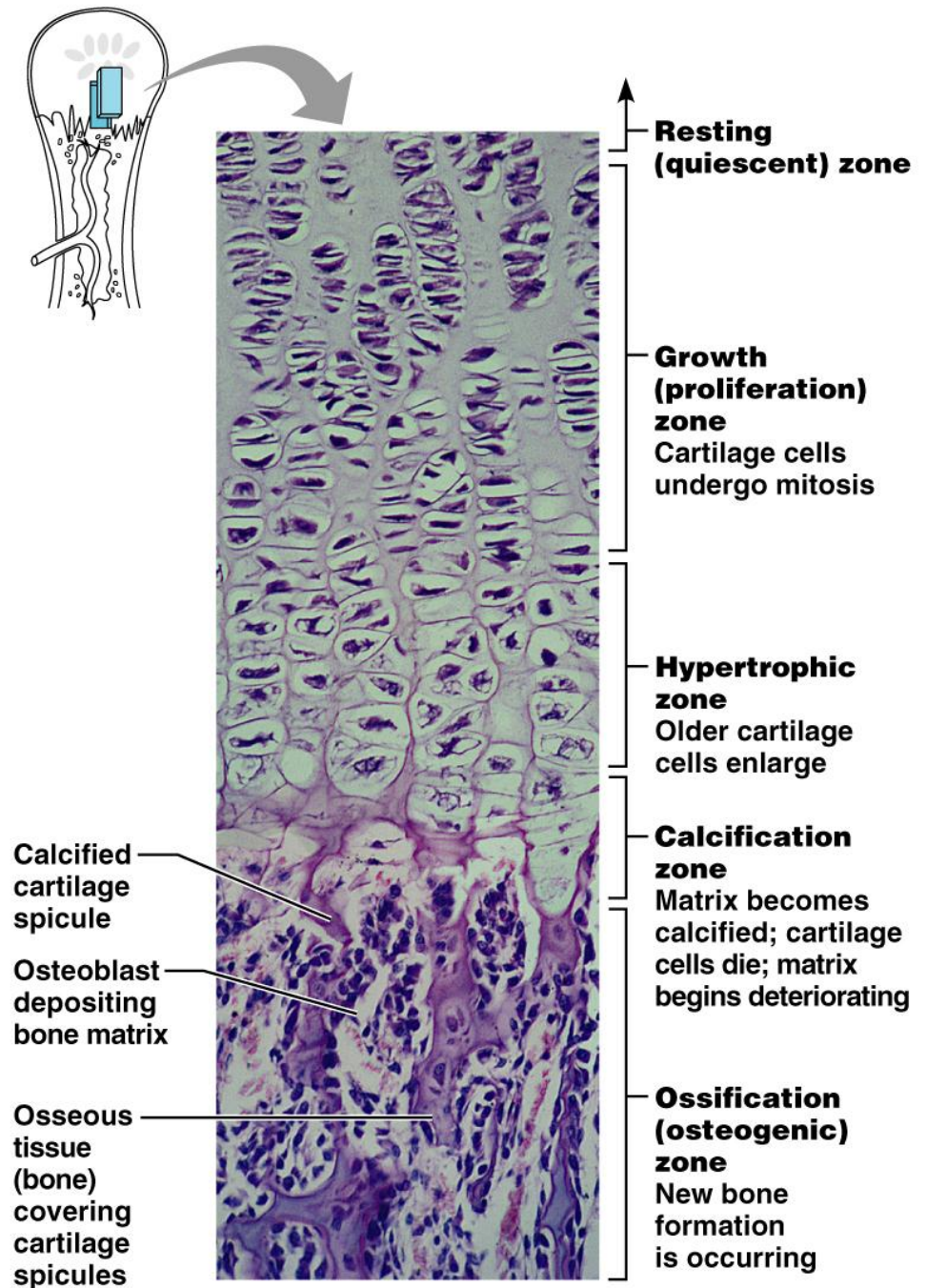
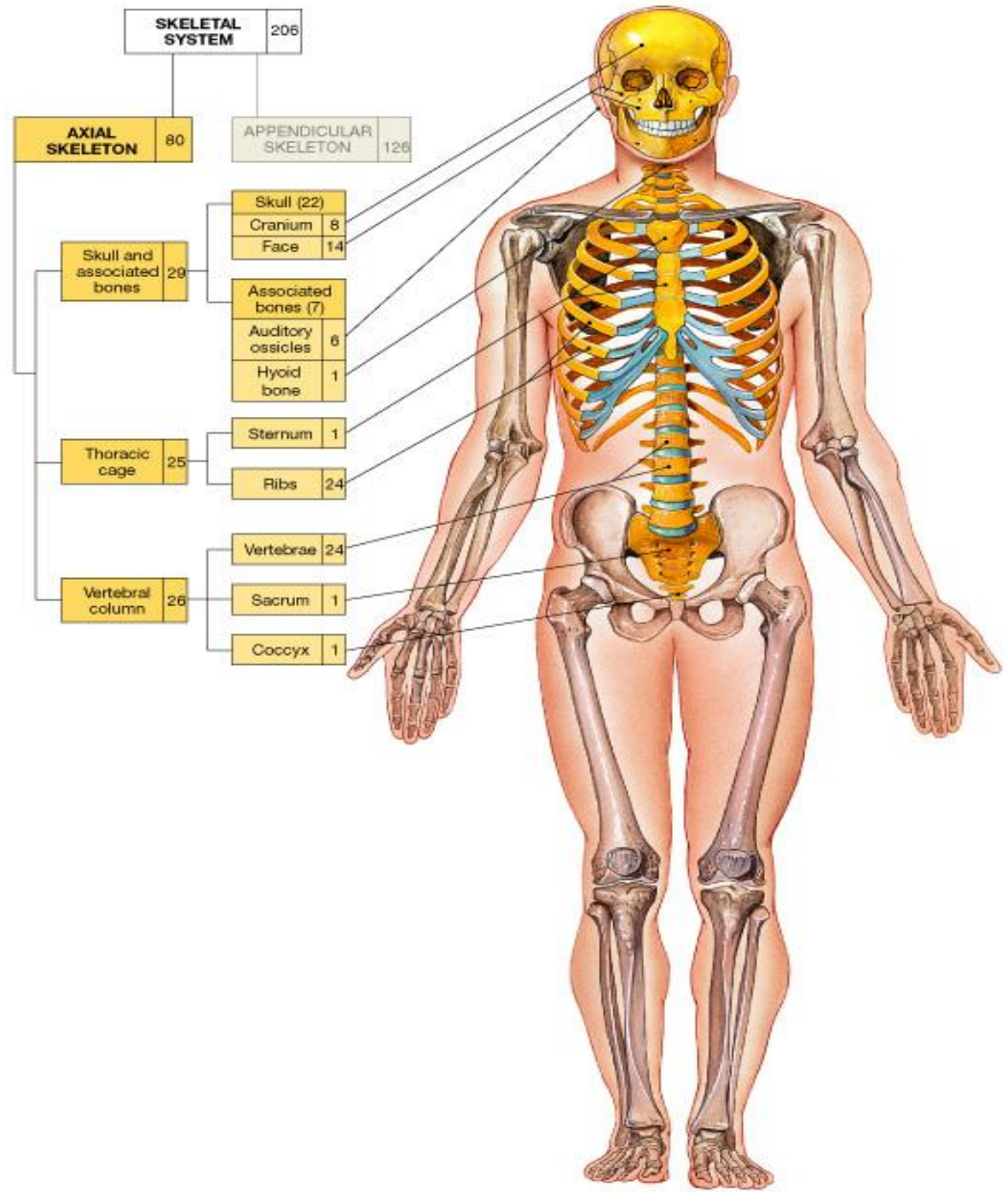


Figure 6.9

80 bones
make up
the axial
skeleton



Skull

Cranial and Facial Bones: 22 bones that enclose and protect the brain and serve as attachment sites for head and neck muscles.

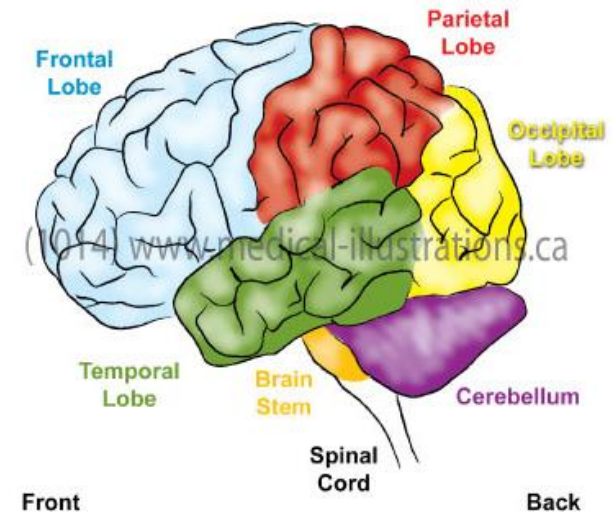
Cranial: made of mainly Flat bones

- Connected by interlocking joints called sutures except for the mandible (TMJ)
- Divided into vault (calvaria) and base with over 85 openings for blood vessels and nerves. *You do not have to learn all of them!*

Facial Bones:

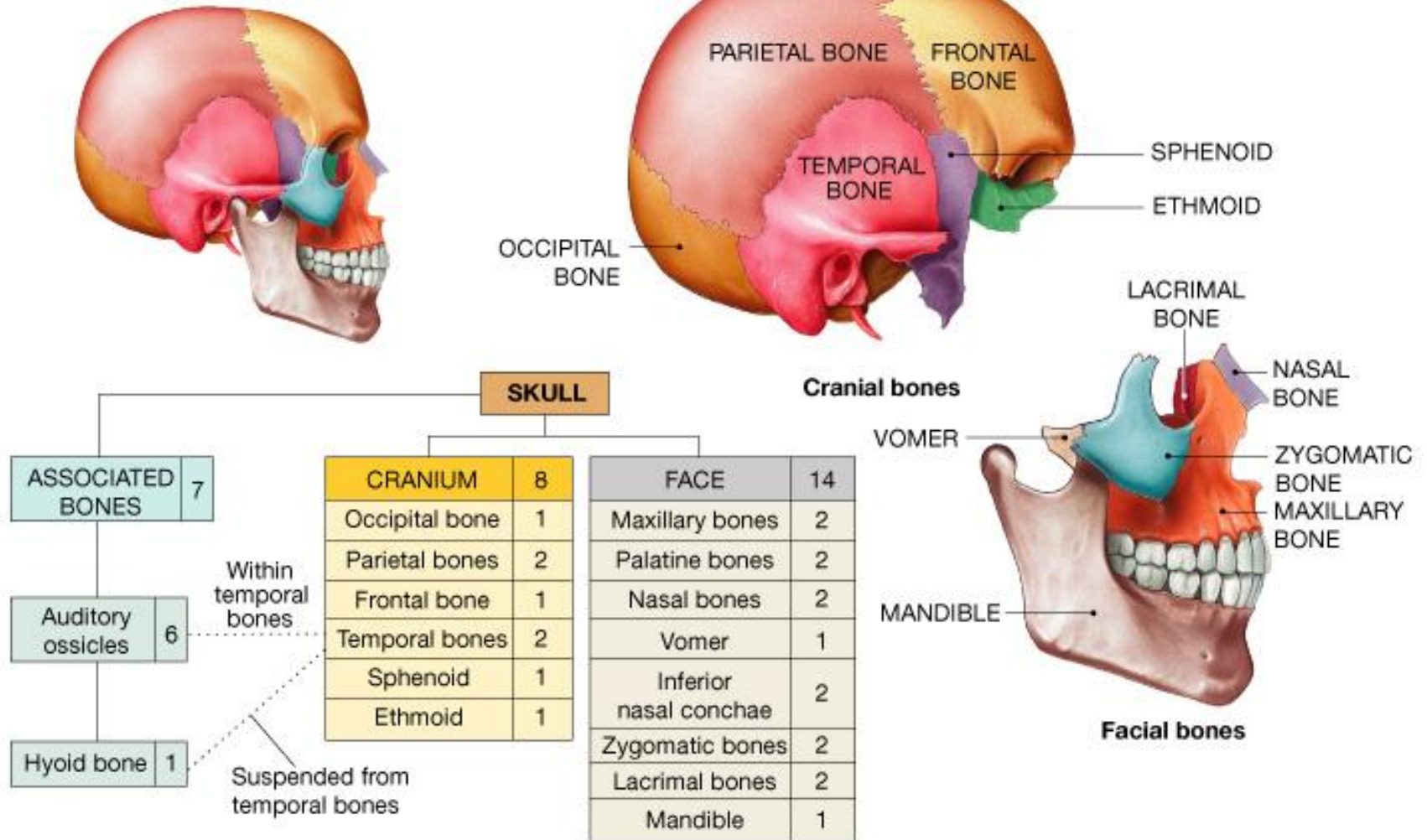
- Framework of face
- Cavities for sense organs (eyes, ears, tongue)
- Provides openings for air and food
- Secures teeth
- Anchors facial muscles

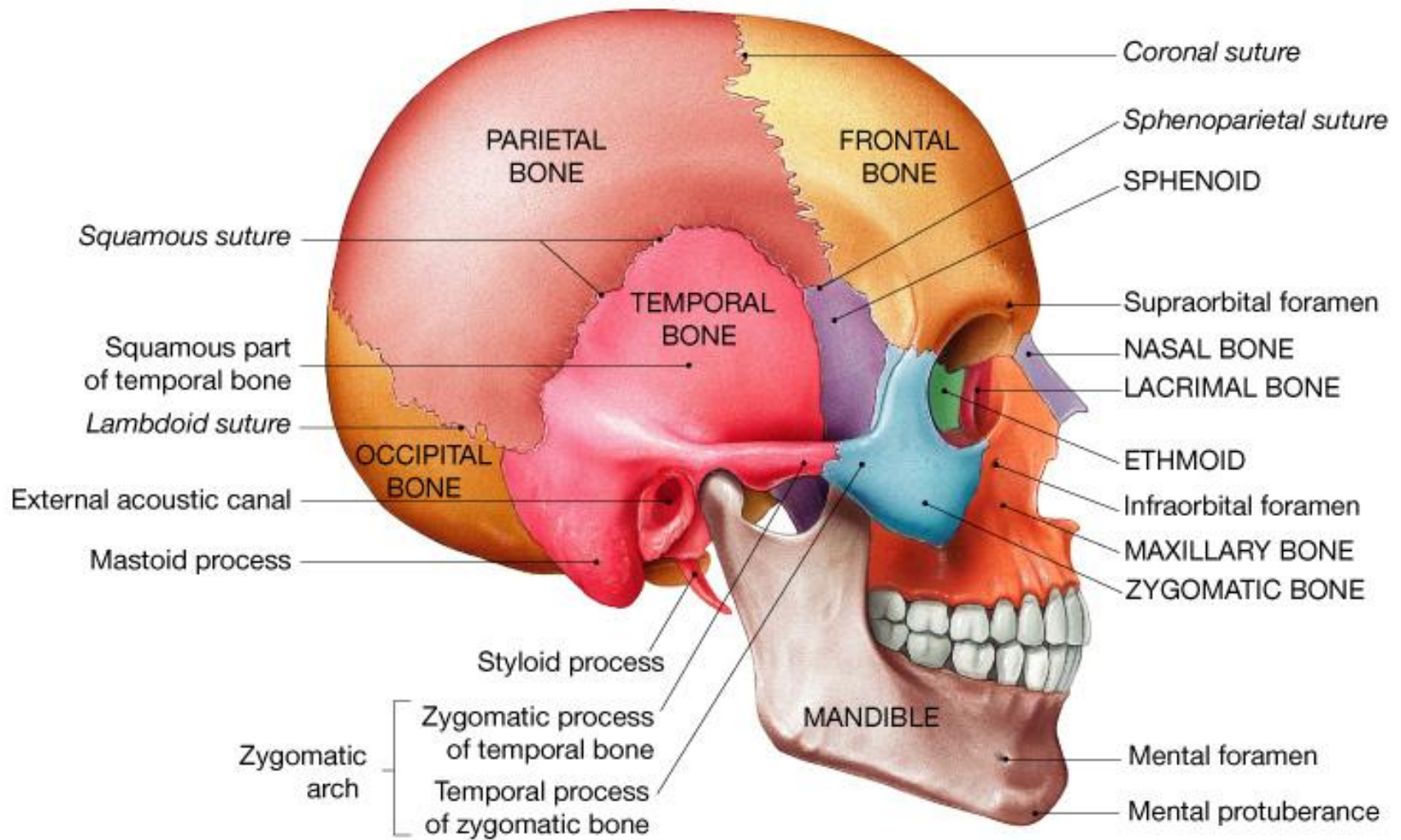
Regions of the Human Brain

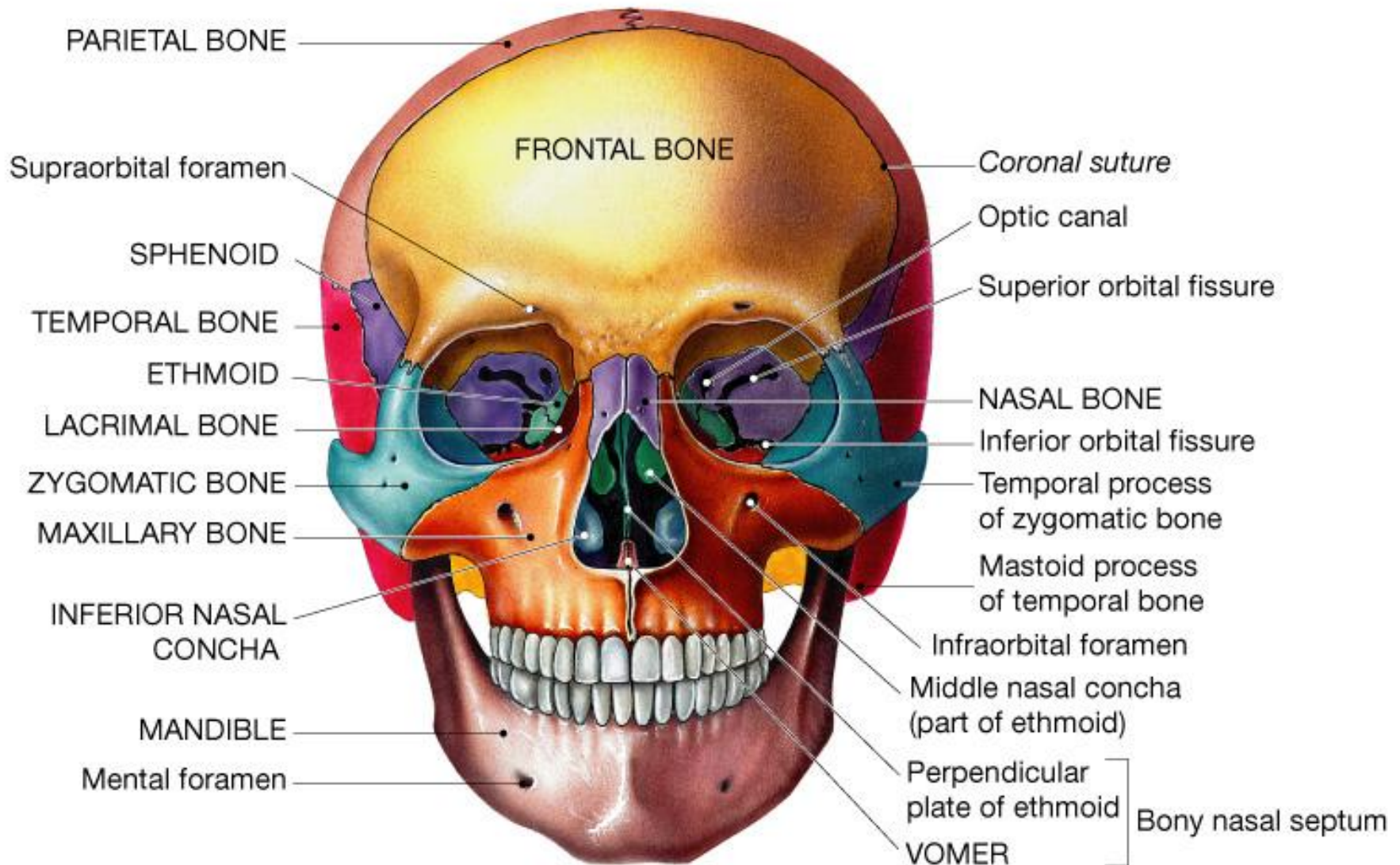


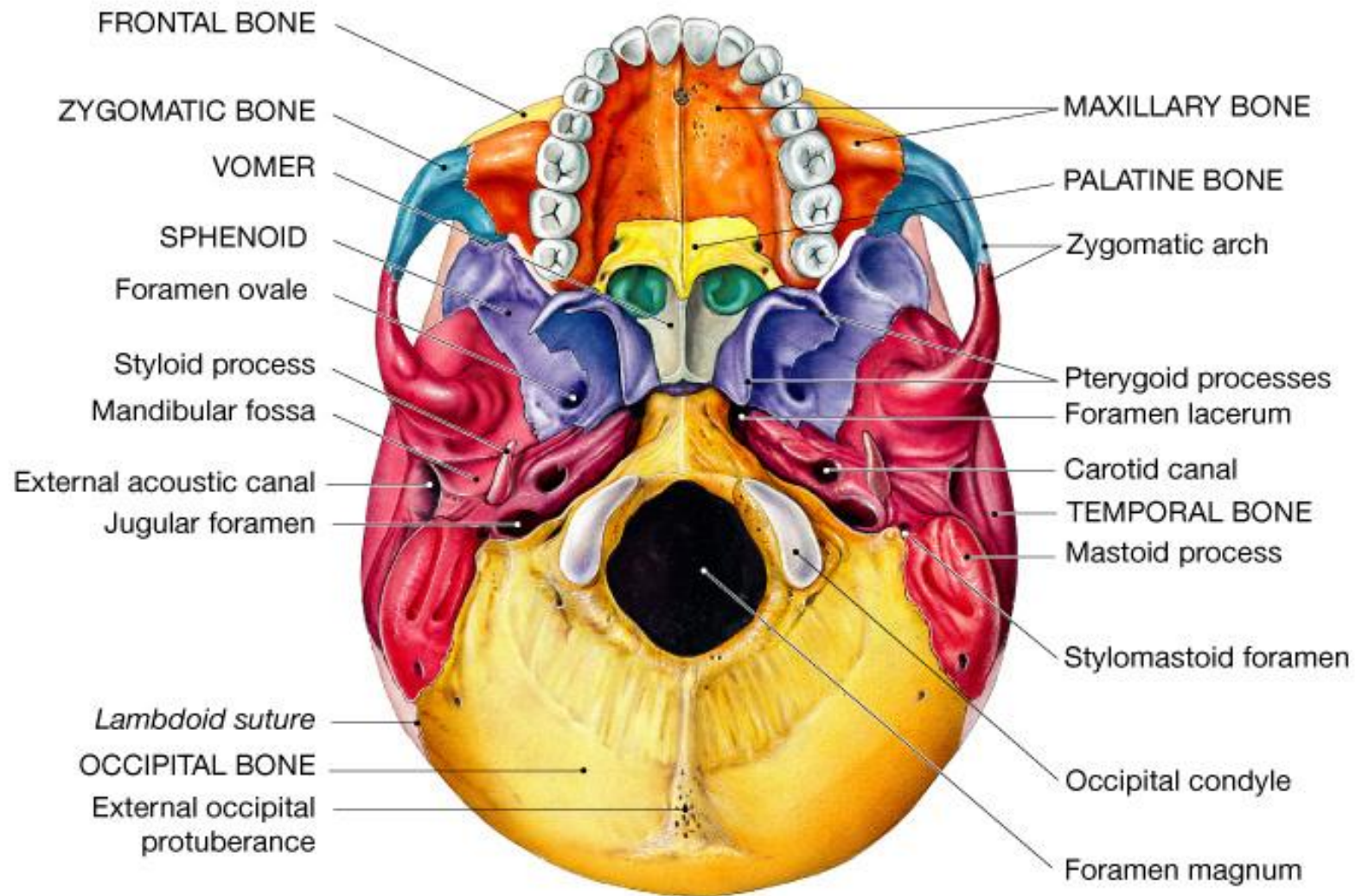
Skull = 22 bones

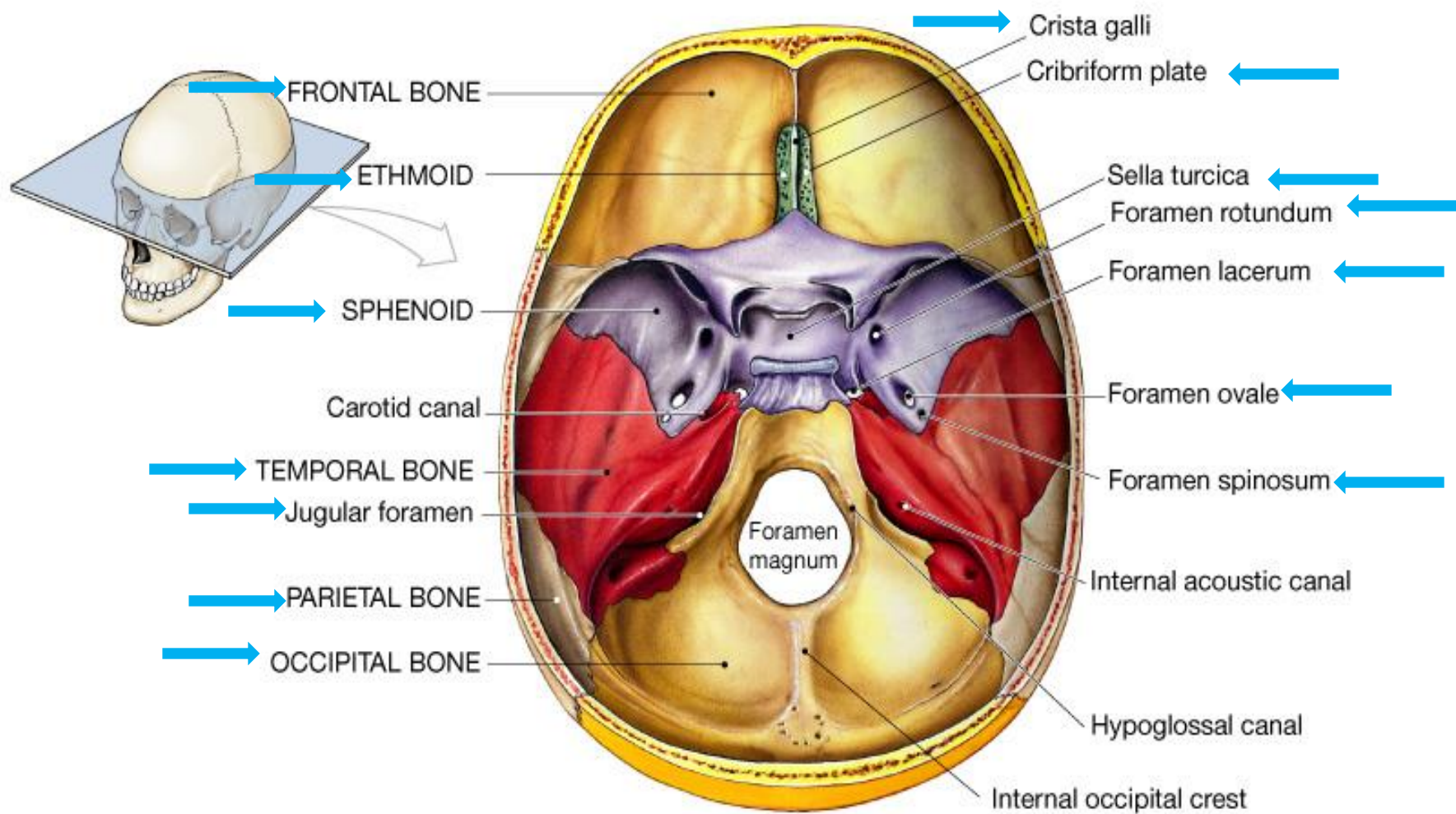
Associated = 7 bones

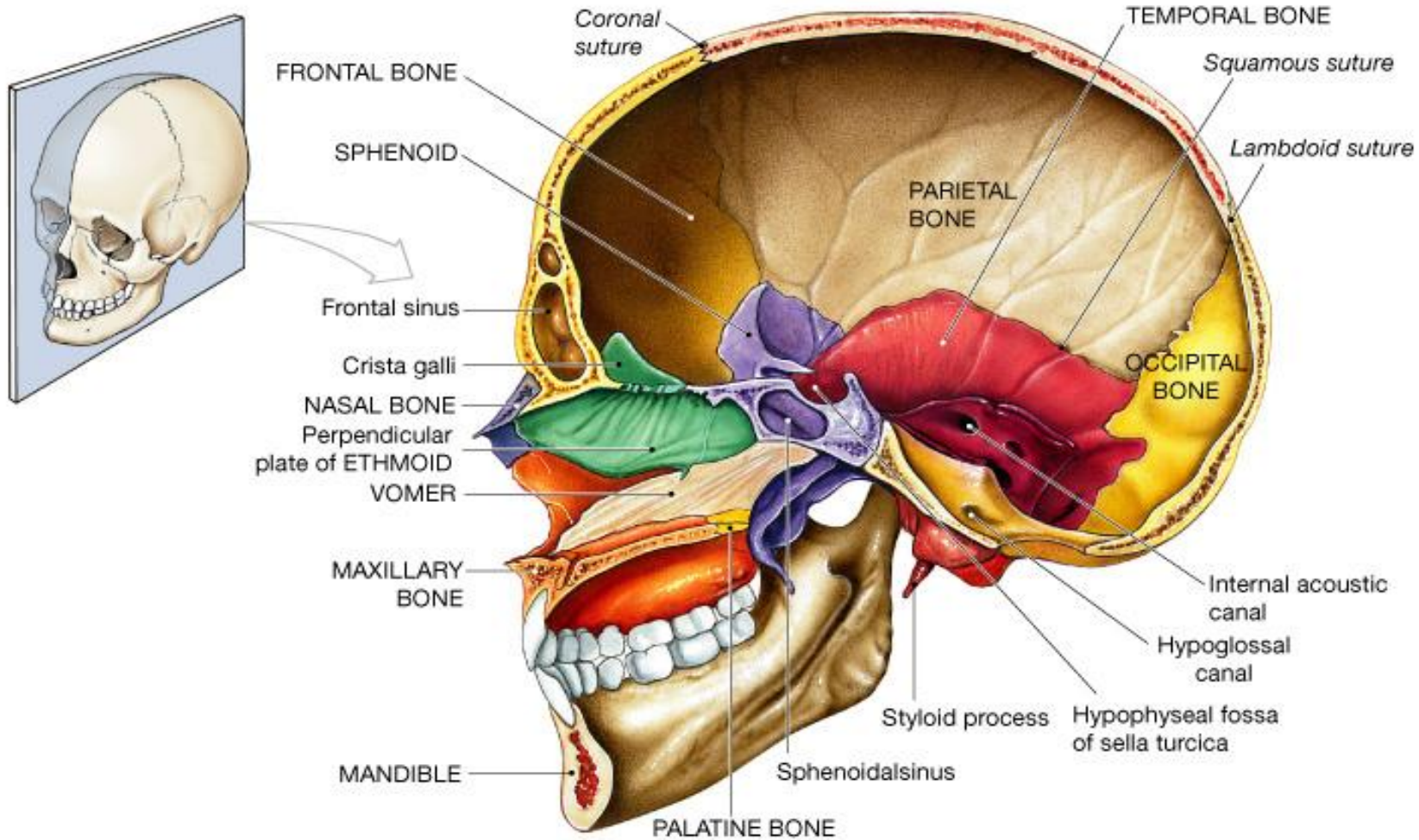






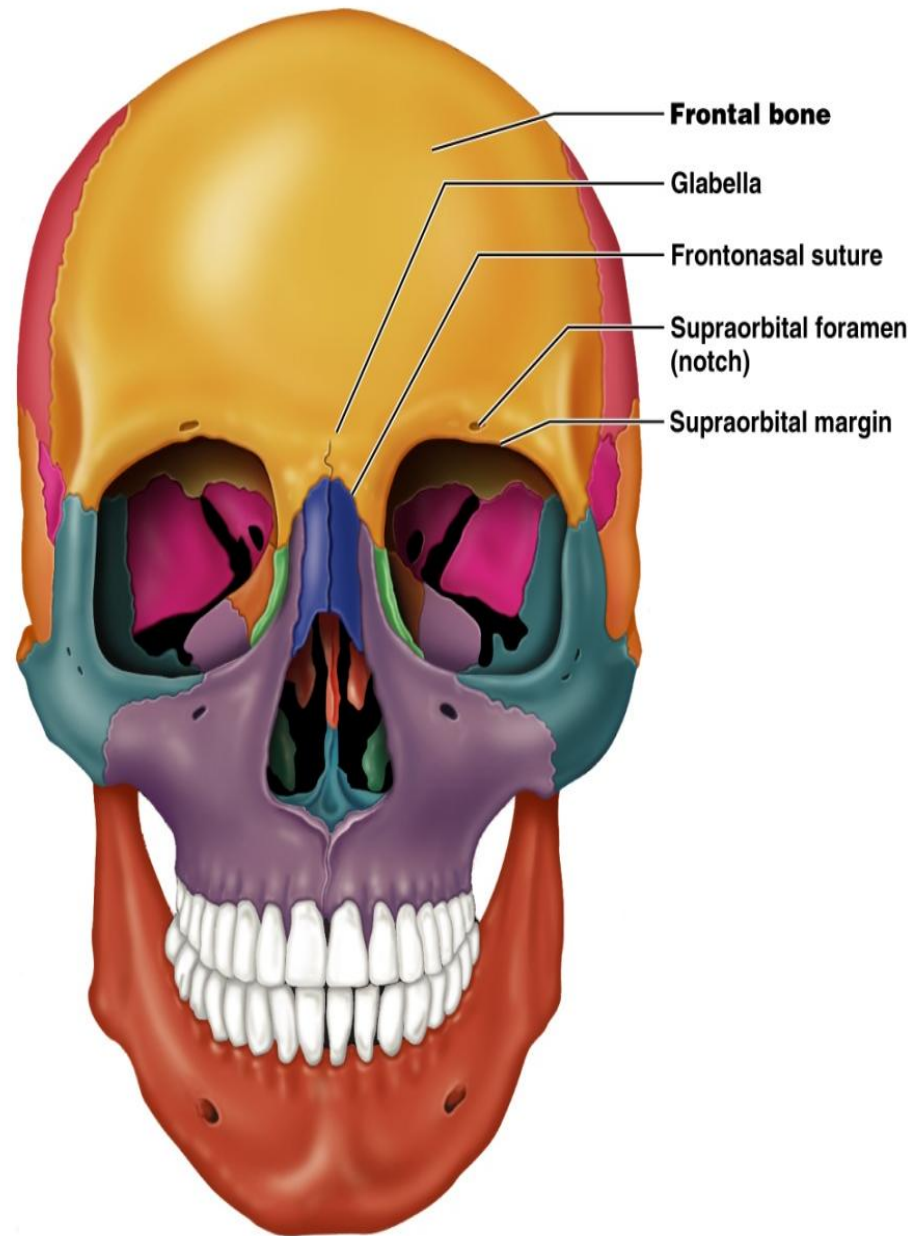






Cranium: Frontal Bone

- Forms the anterior portion of the cranium
- Articulates posteriorly with the parietal bones via the coronal suture
- Markings you need to know:
 - supraorbital foramen
 - frontal sinuses (internal and lateral to the glabella)



(a)

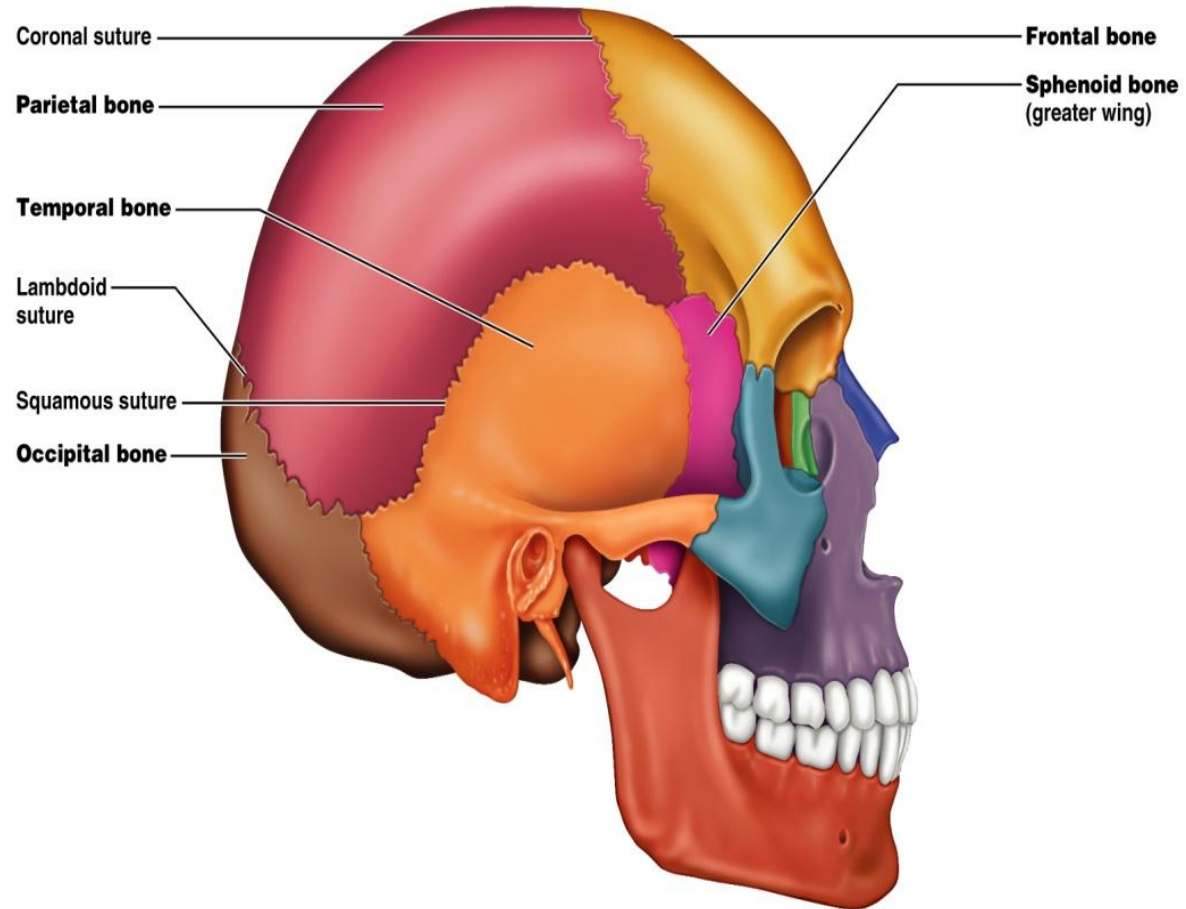
Figure 7.2a

Parietal Bones

Four sutures mark the articulations of the parietal bones

- **Coronal suture** - articulation between parietal bones and frontal bone anteriorly
- **Sagittal suture** - where right and left parietal bones meet superiorly
- **Lambdoid suture** - where parietal bones meet the occipital bone posteriorly
- **Squamosal or squamous suture** - where parietal and temporal bones meet

- Parietal bone covers parietal and temporal lobes of brain



(a)

Occipital Bone

- Forms most of skull's posterior wall and base
- Joints include lambdoid (parietal) and occipitomastoid (temporal)
- Major markings you need to know:
 - foramen magnum (spinal cord exit)
 - occipital condyles (articulate with atlas)
 - Superior and inferior nuchal line which secure many back and neck muscles

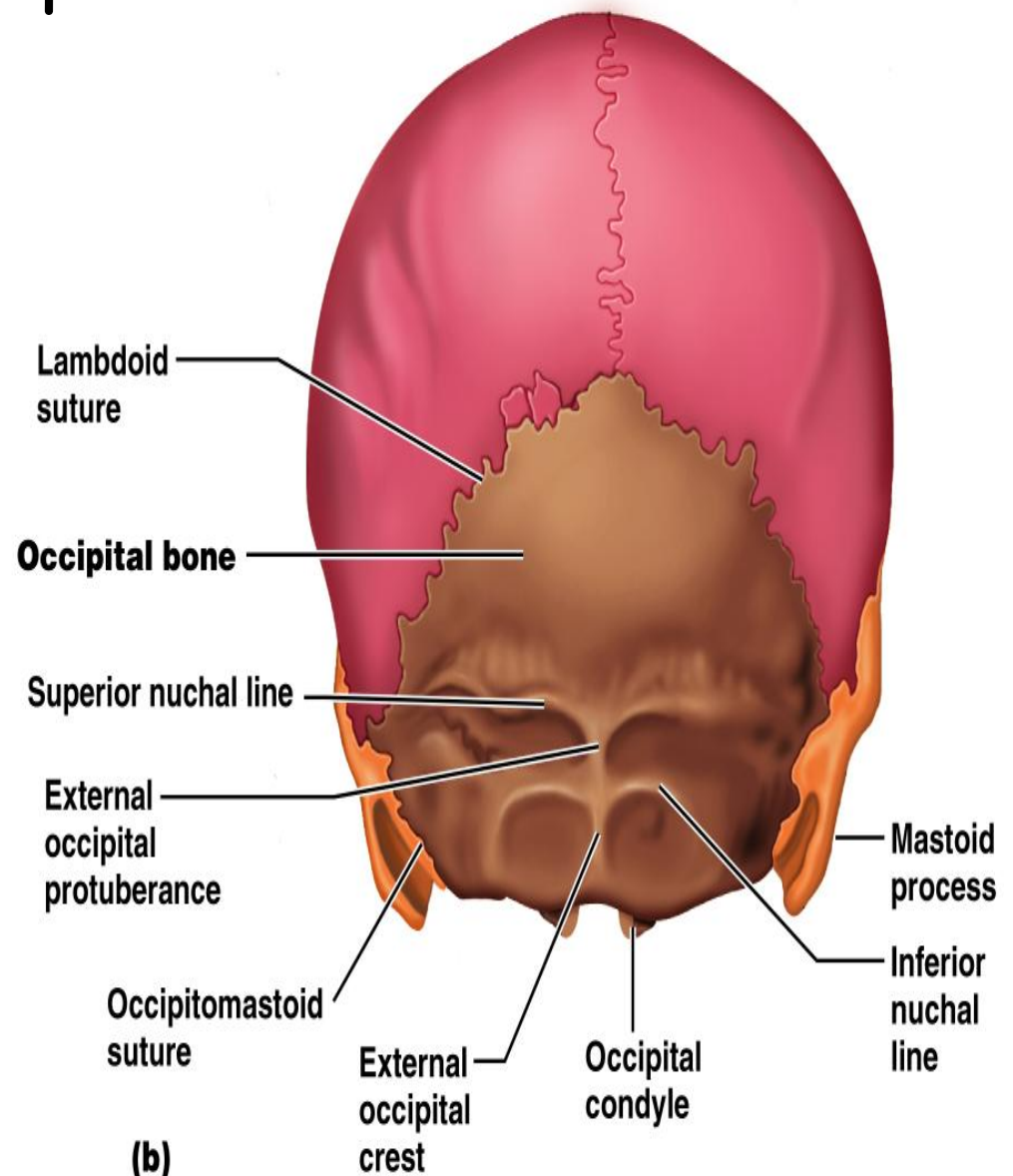
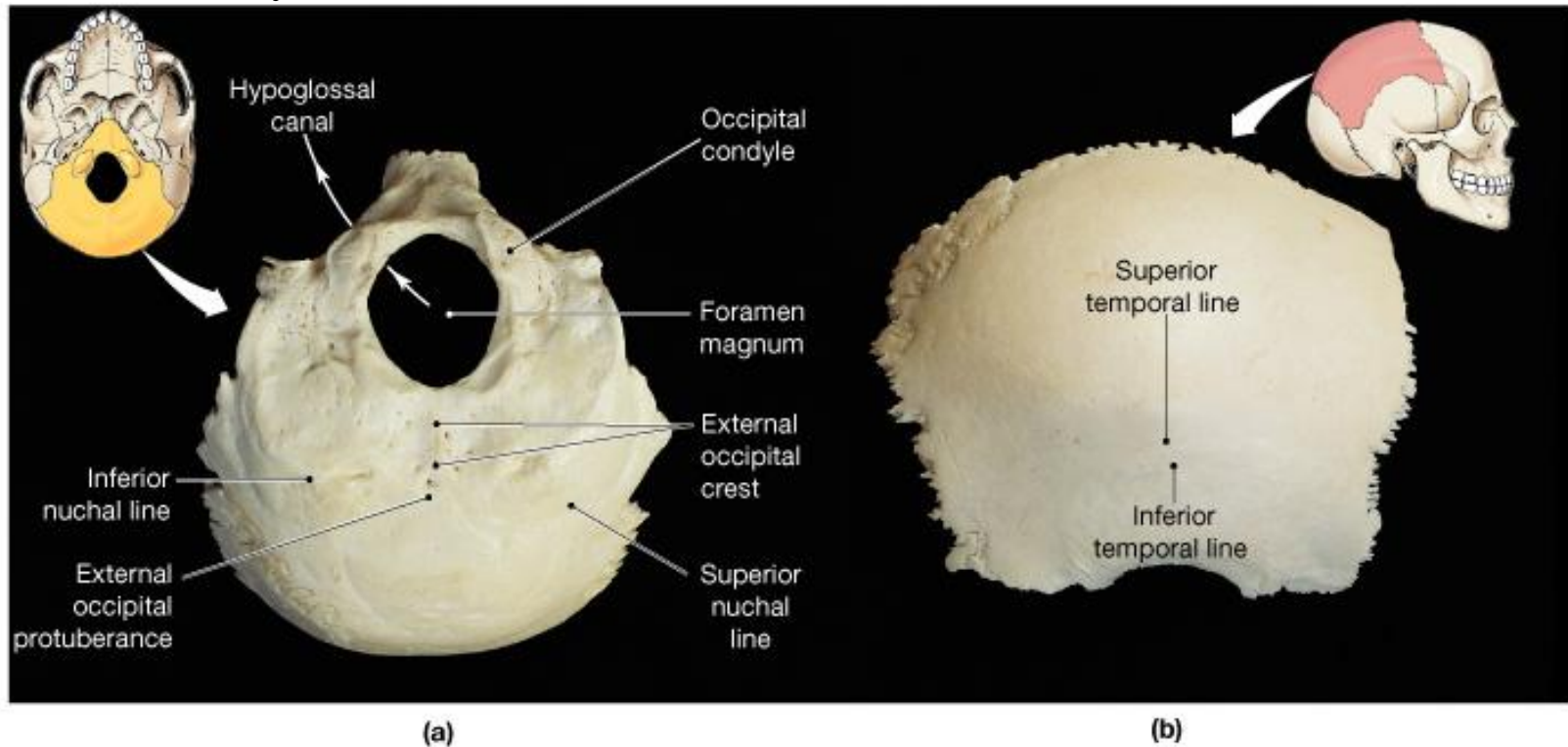


Figure 7.2b

Occipital bone Parietal bones (2)



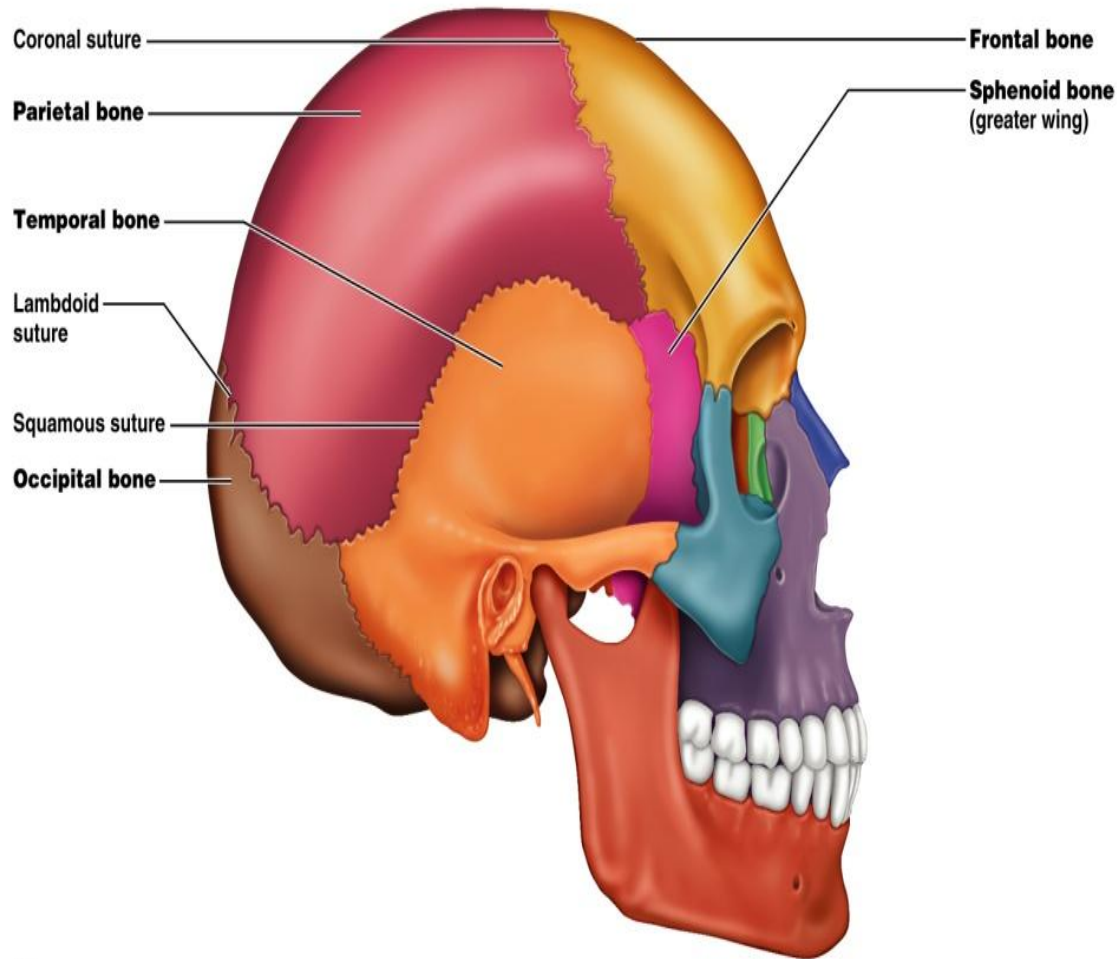
Temporal Bones

Divided into four major regions:

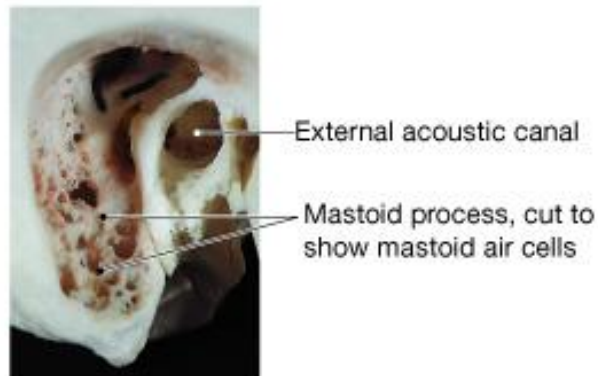
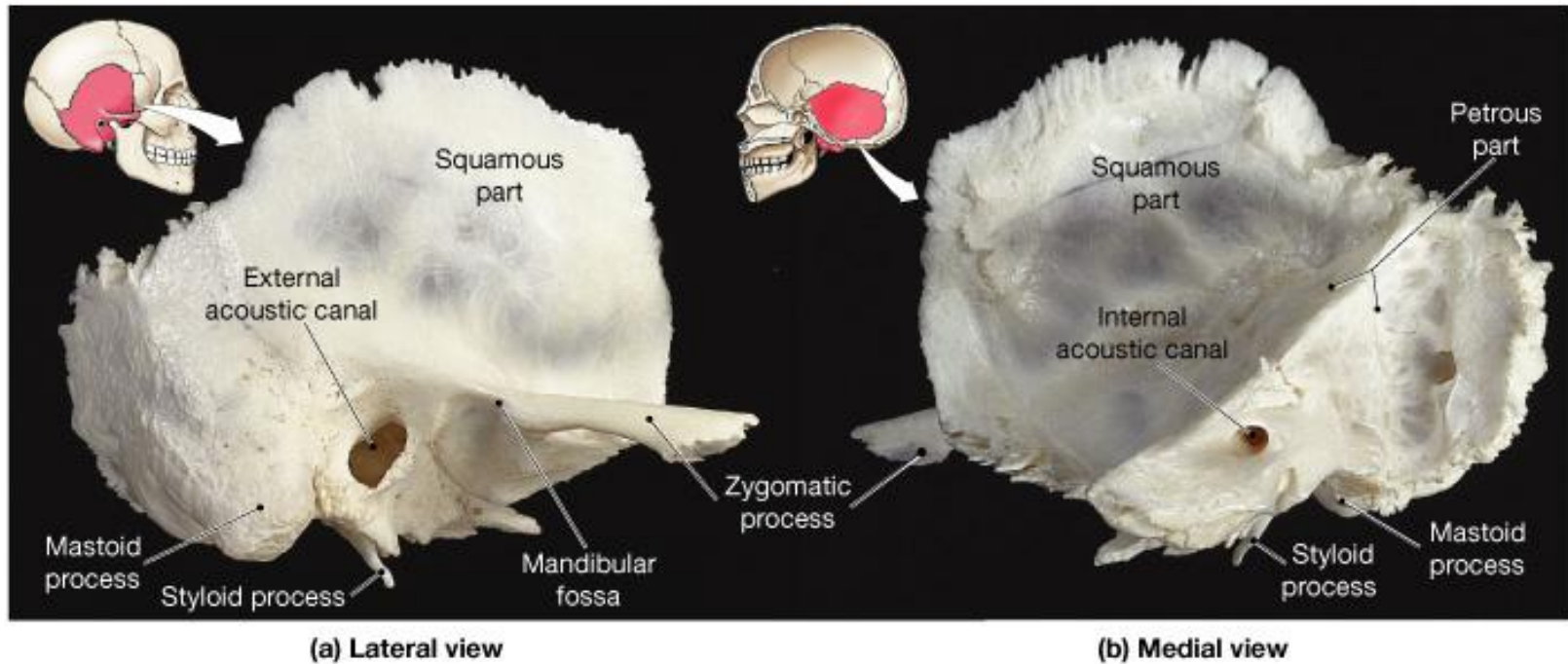
- squamous (by squamous suture)
- tympanic (surrounds external ear canal)
- mastoid
- petrous (base with sphenoid supports temporal lobe of brain, houses ear cavities - visible from inside)

Major markings you need to know:

- external acoustic (auditory) meatus
- styloid process
- zygomatic process
- mastoid process
- mandibular fossa
- jugular foramen



(a)



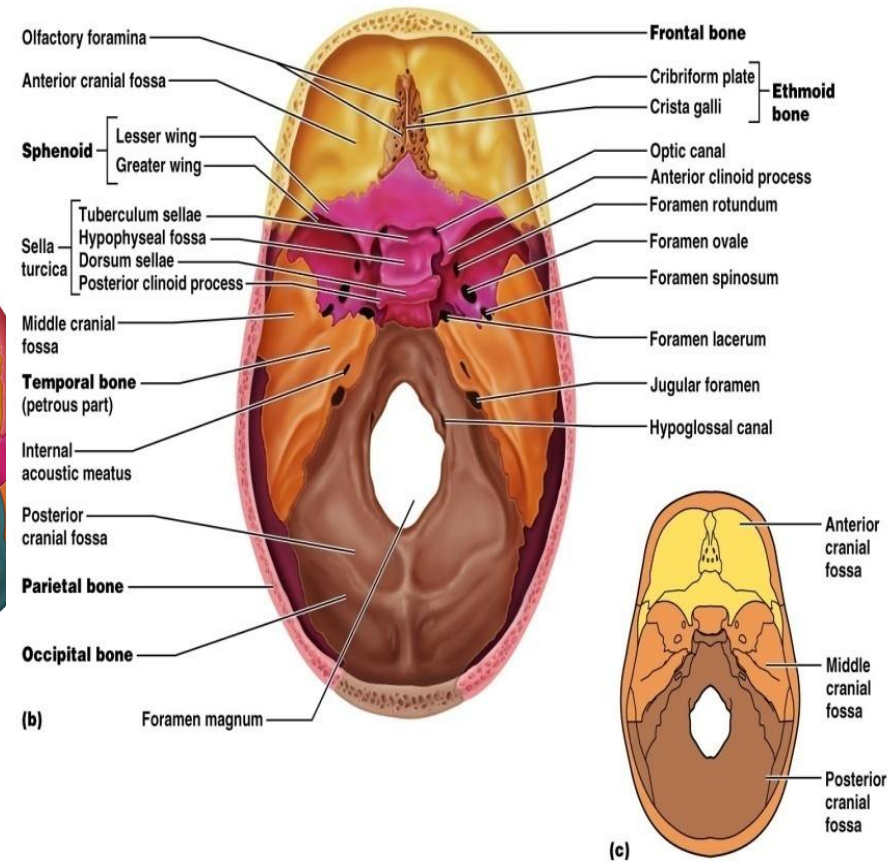
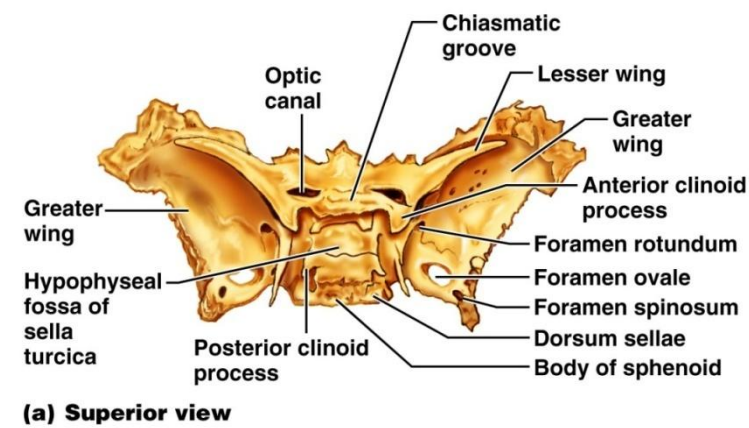
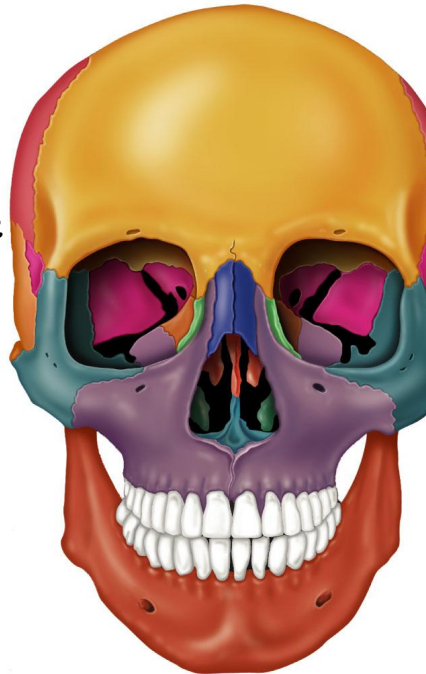Temporal bones (2)

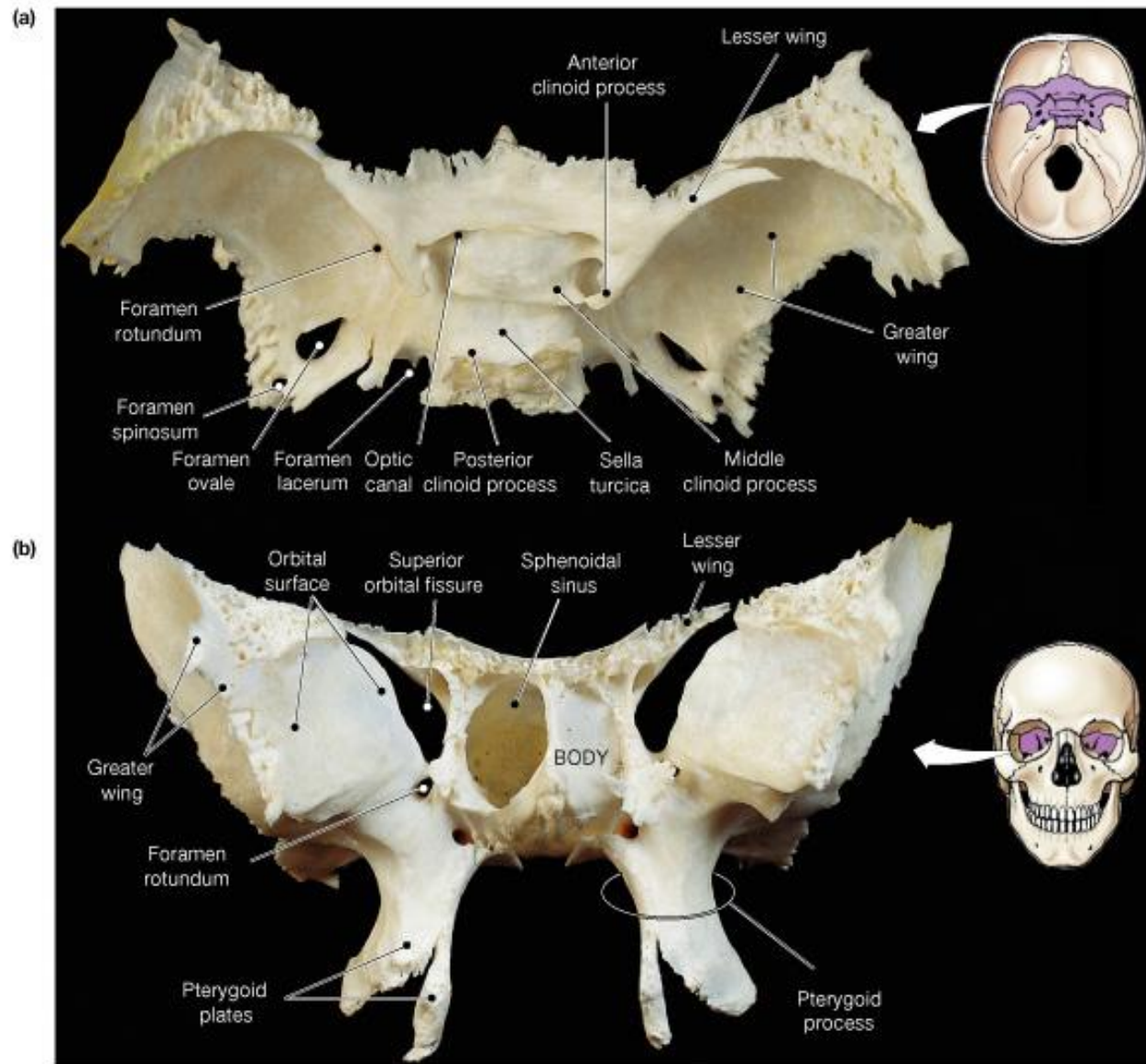
Sphenoid Bone

- Butterfly-shaped bone that spans the width of the middle cranial fossa
- Forms the central wedge that articulates with all other cranial bones
- Consists of a central body (w/sphenoid sinuses) and 3 processes:
 - greater wings
 - lesser wings
 - pterygoid

Major markings you need to know:

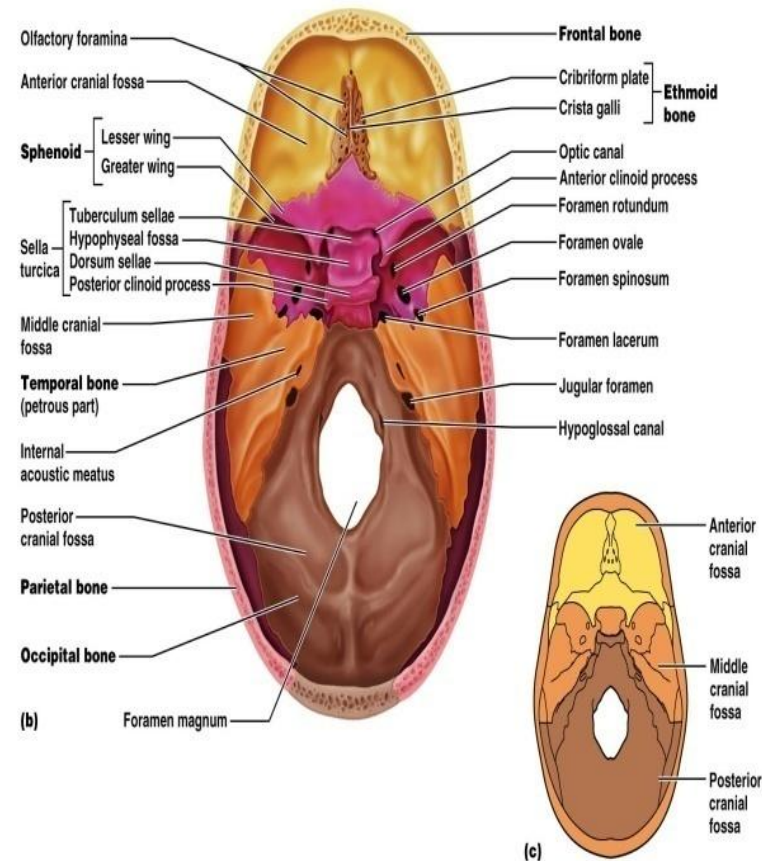
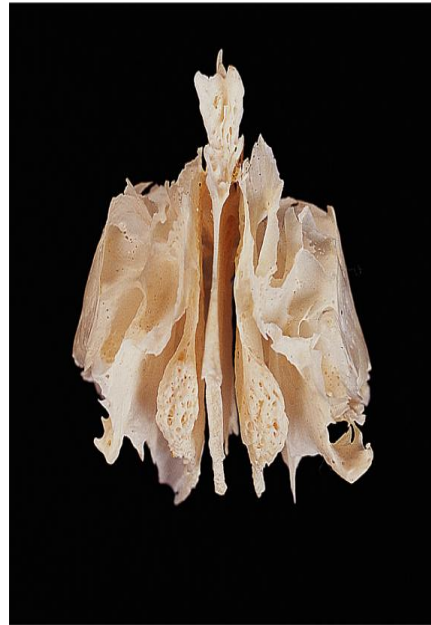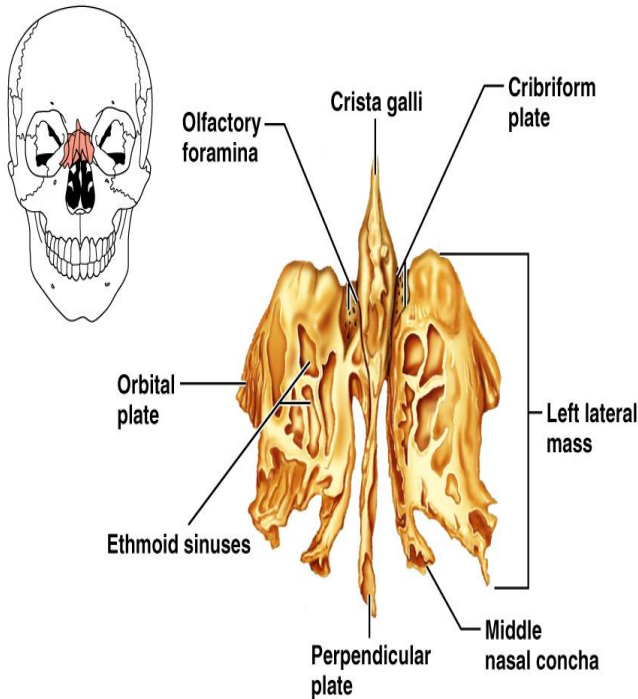
- sella turcica
- optic foramen
- greater wing
- lesser wing
- superior orbital fissure
- foramen ovale
- foramen rotundum
- foramen spinosum





Sphenoid

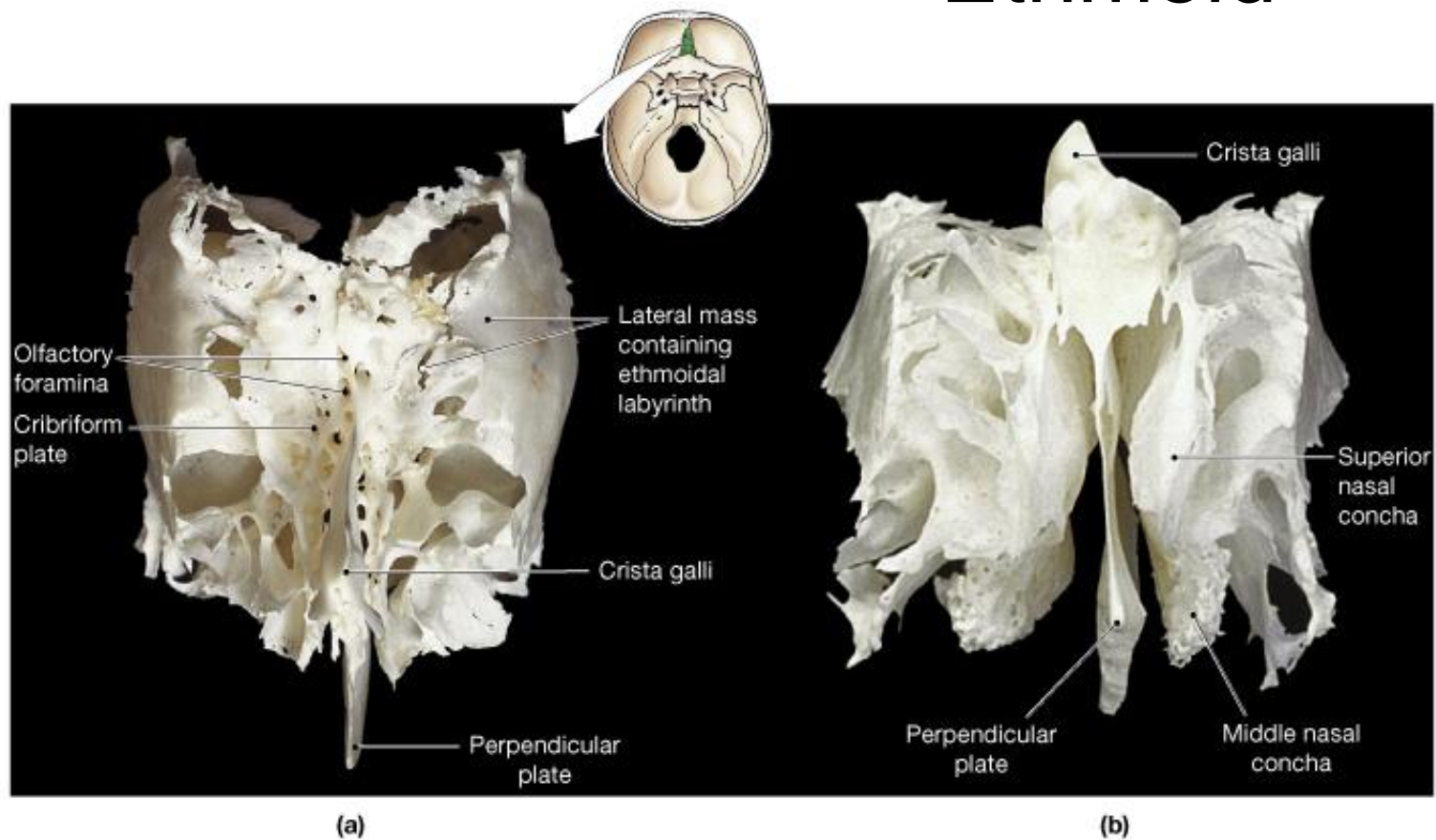
Ethmoid Bone



Copyright © 2006 Pearson Education, Inc., publishing as Benjamin Cummings.

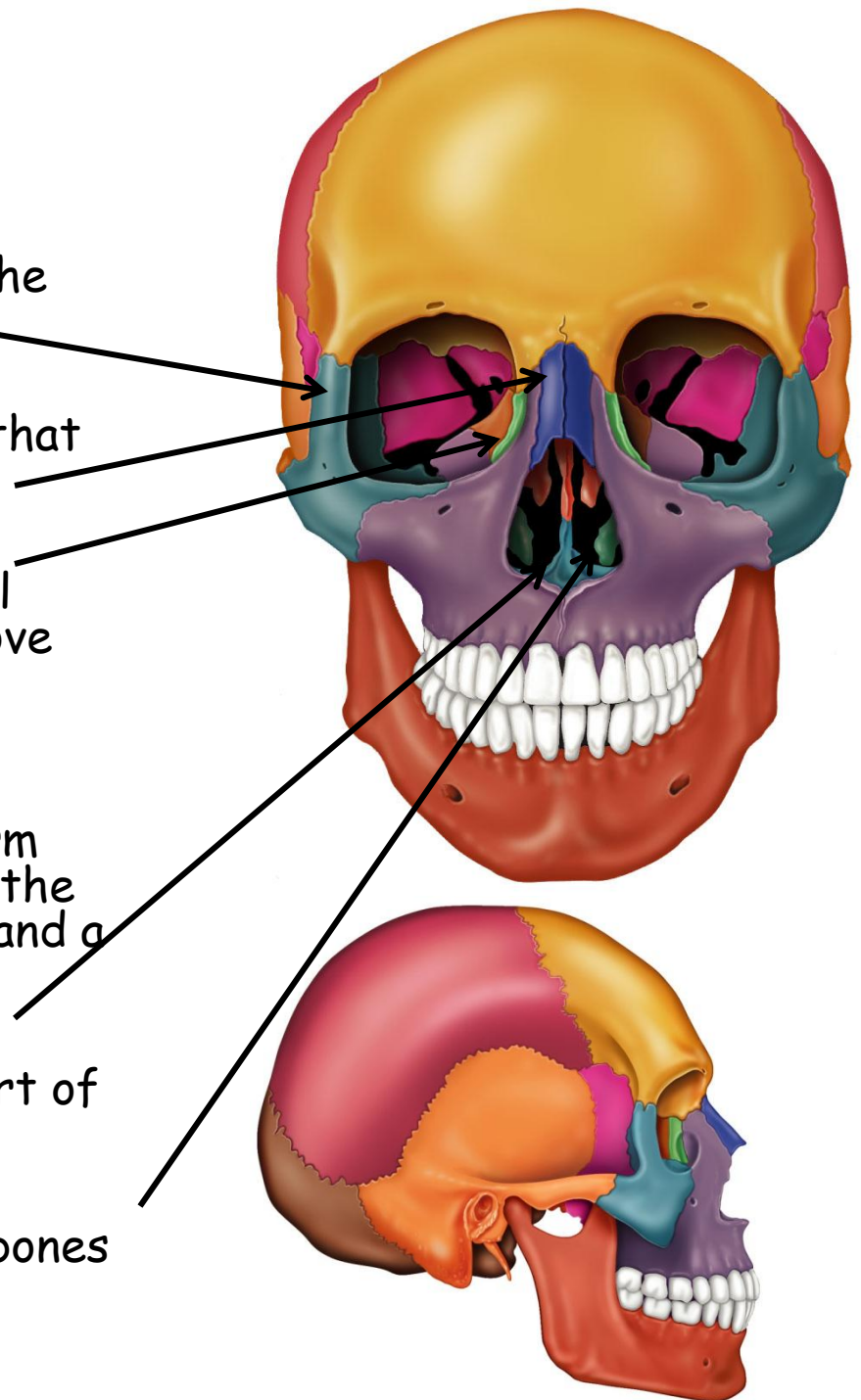
- Deepest of the skull bones; lies between the sphenoid and nasal bones
- Forms most of the bony area between the nasal cavity and the orbits
- Major markings you need to know: the cribriform plate (roof of nasal cavities with opening for olfactory nerves), crista galli (dura attaches here), perpendicular plate (forms nasal septum)

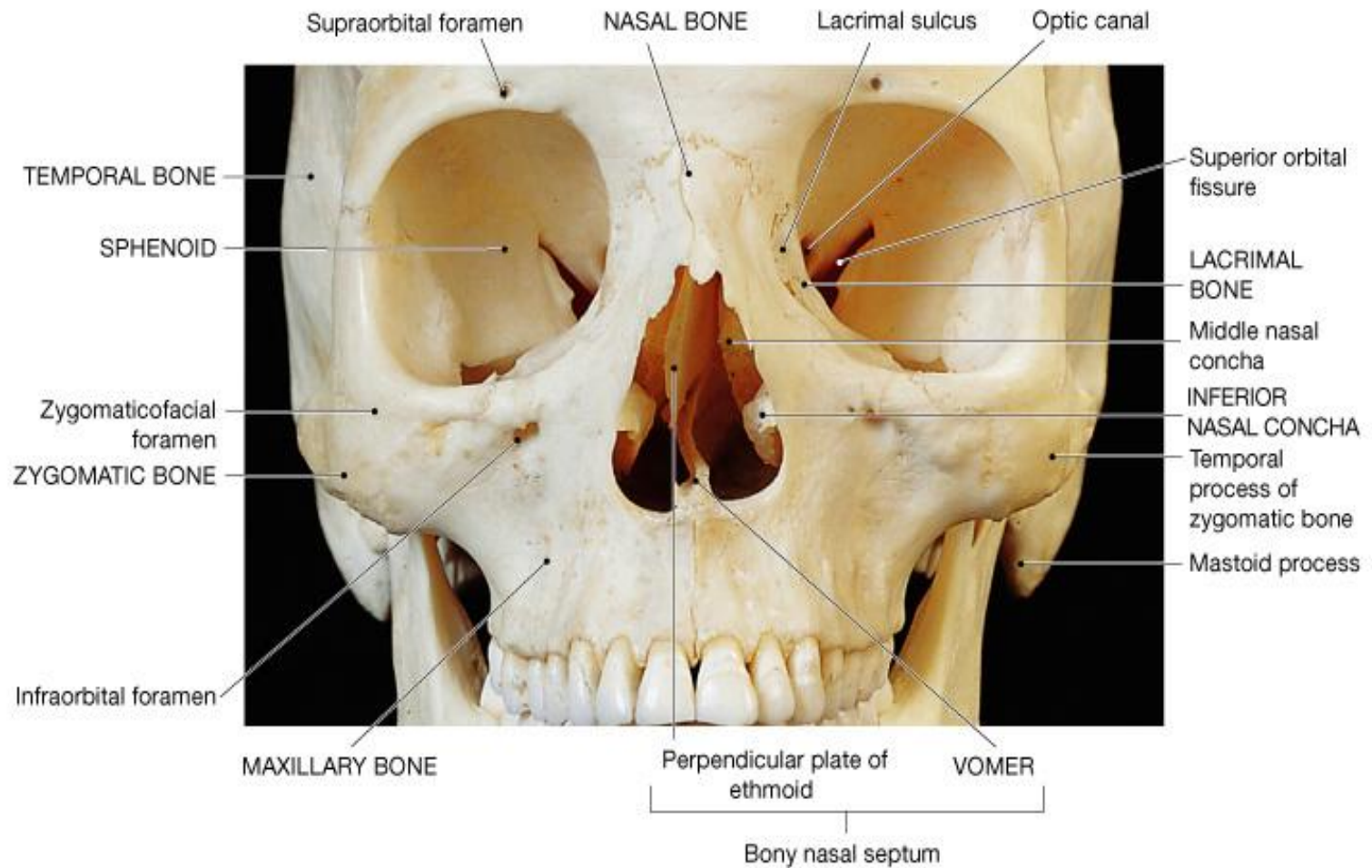
Ethmoid



Skull: Other Bones

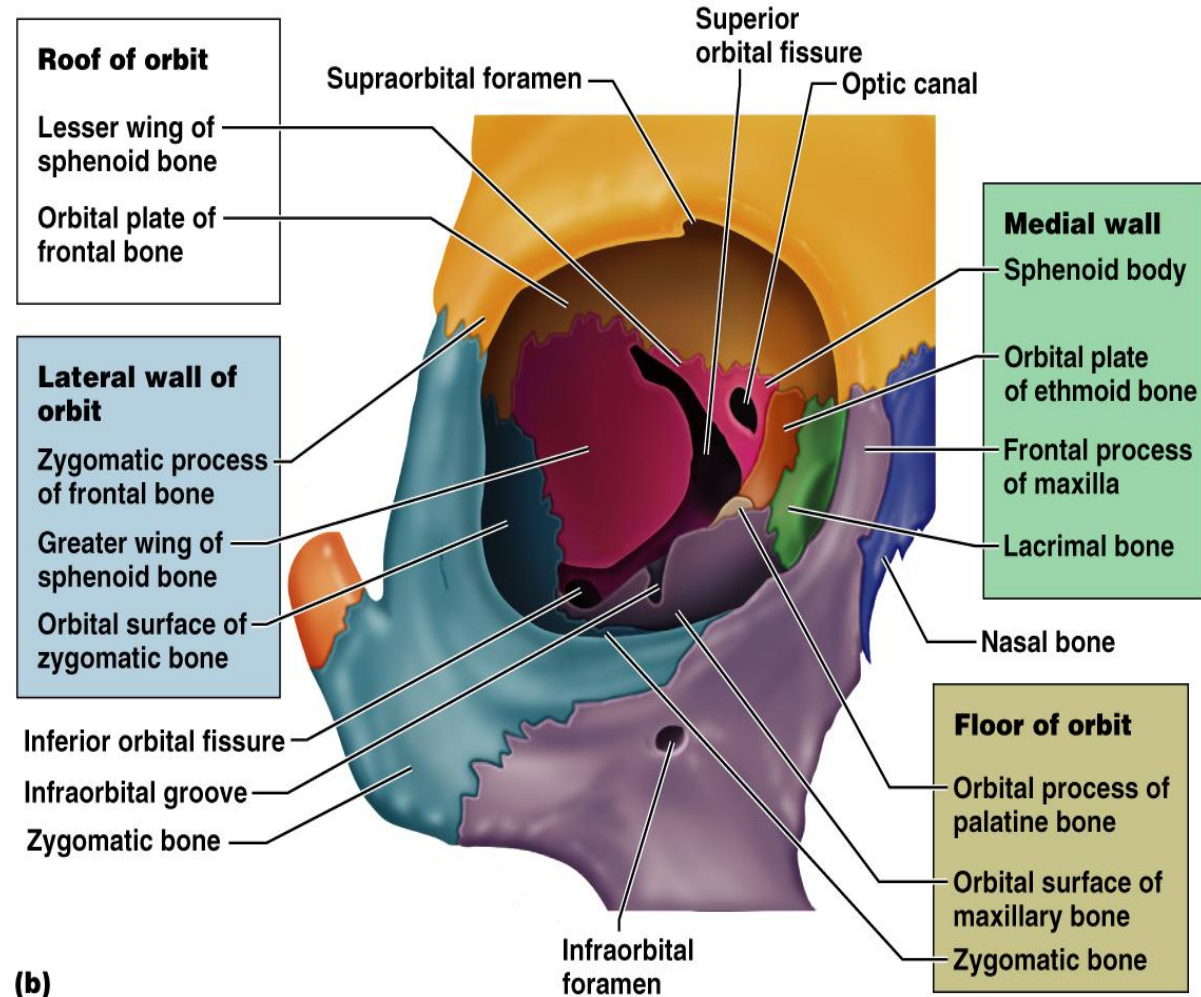
- **Zygomatic:** Irregularly shaped bones (cheekbones) that form the cheeks and the inferior-lateral margins of the orbits
- **Nasal bones** - thin medially fused bones that form the bridge of the nose
- **Lacrimal bones** - contribute to the medial walls of the orbit and contain a deep groove called the lacrimal fossa that houses the lacrimal glands
- **Palatine bones** - two bony plates that form the posterior portion of the hard palate, the postero-lateral walls of the nasal cavity, and a small part of the orbits
- **Vomer** - plow-shaped bone that forms part of the nasal septum
- **Inferior nasal conchae** - paired, curved bones in the nasal cavity that form part of the lateral walls of the nasal cavity





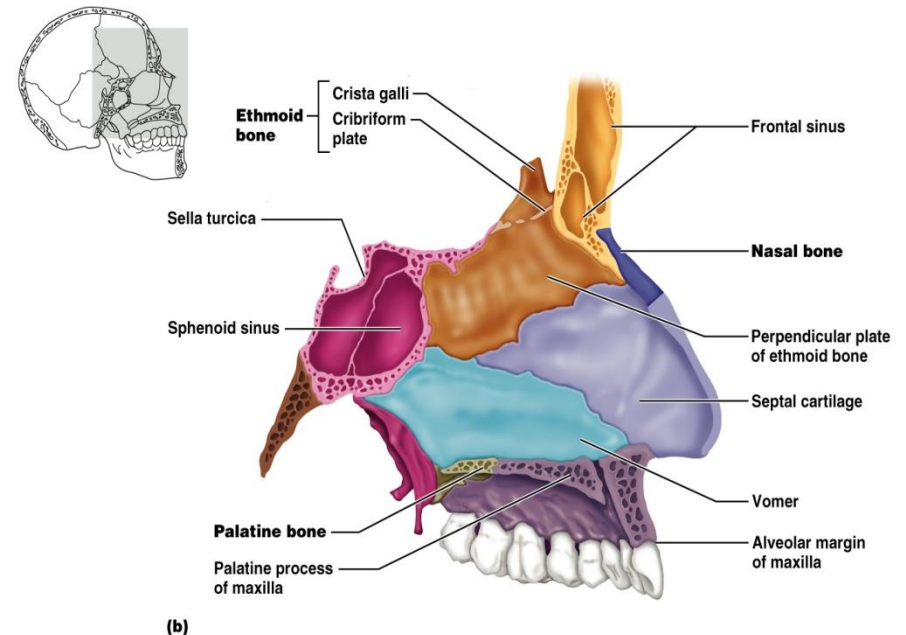
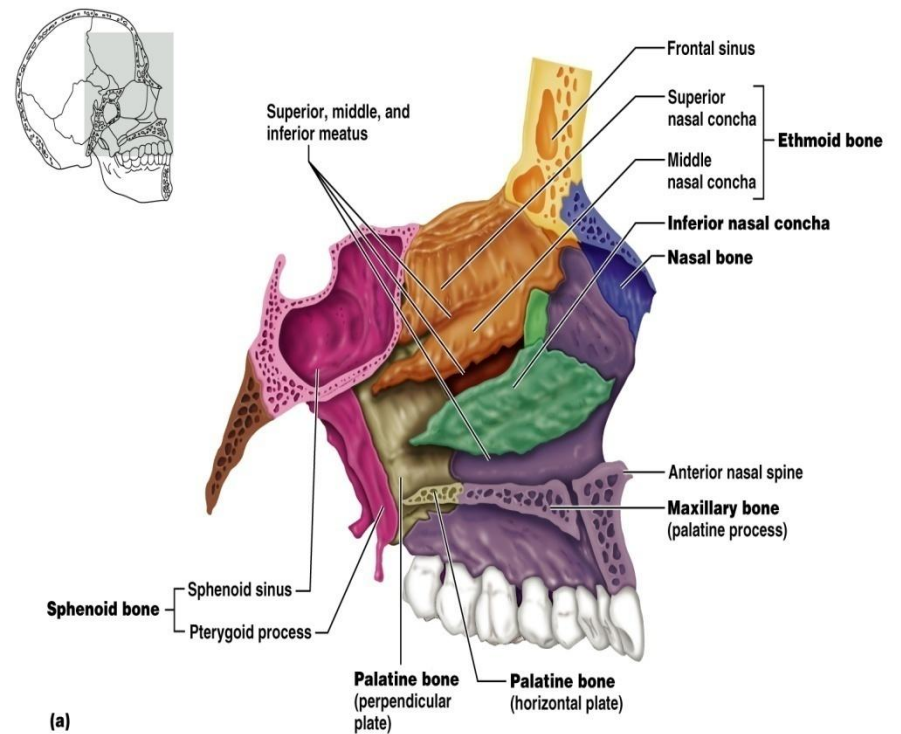
Orbits

- Bony cavities in which the eyes are firmly encased and cushioned by fatty tissue
- Formed by parts of seven bones - frontal, sphenoid, zygomatic, maxilla, palatine, lacrimal, and ethmoid



Nasal Cavity

- Constructed of bone and hyaline cartilage
- Roof - formed by the **cribriform plate of the ethmoid bone**
- Lateral walls - formed by the superior and middle conchae of the ethmoid, the perpendicular plate of the palatine bone, and the inferior nasal conchae of ethmoid
- Floor - formed by palatine process of the maxillae and palatine bone
- Nasal septum divides nasal cavity: vomer inferiorly, ethmoid bone superiorly + septal cartilage.
- Nasal septum has mucus secreting epithelia, nasal conchae increase air turbulence - traps more particles.

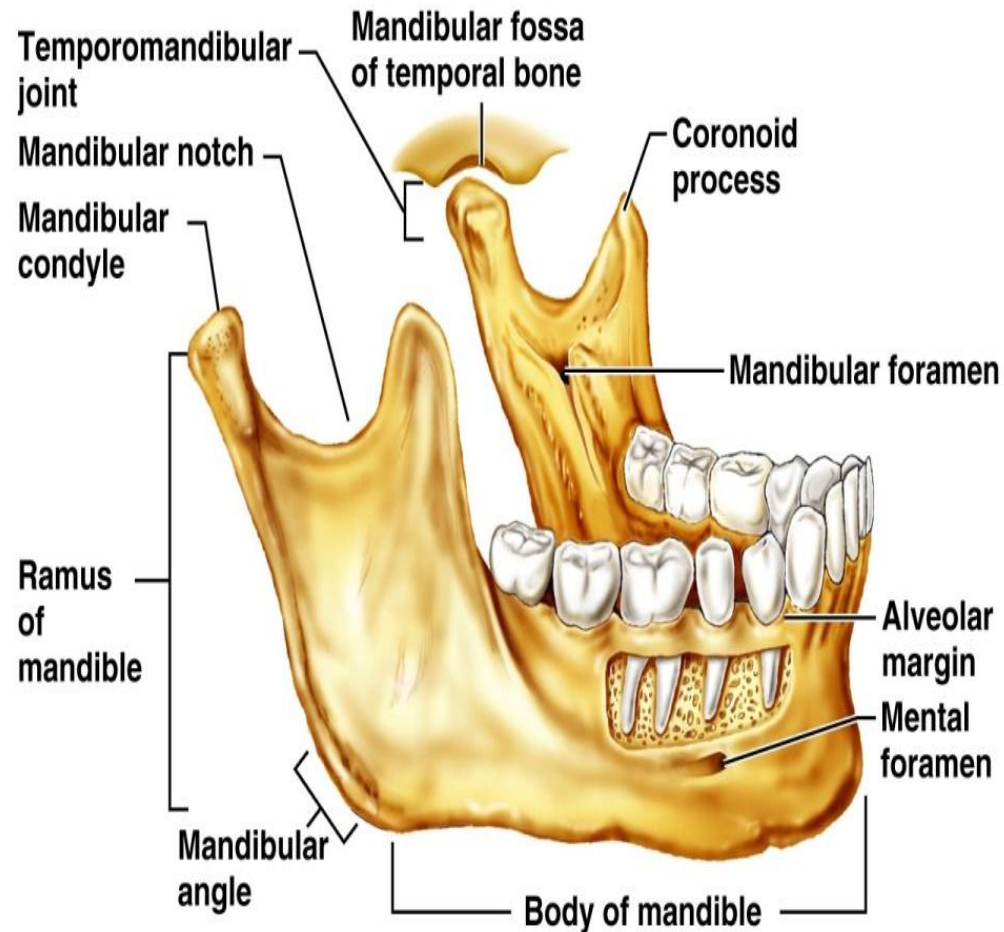


Facial Bones: Mandible and Its Markings

- There are 14 facial bones
- The mandible (lower jawbone) is the largest, strongest bone of the face
- Forms chin
- Anchors the lower teeth
- Mandibular foramen - exit for sensory nerves from teeth where dentists inject novocaine

Markings to Know:

- body
- mandibular foramen
- mental foramen
- mandibular notch
- alveolar process (margin)
- condylar process (has mandibular condyle at its superior end)
- coronoid process
- ramus



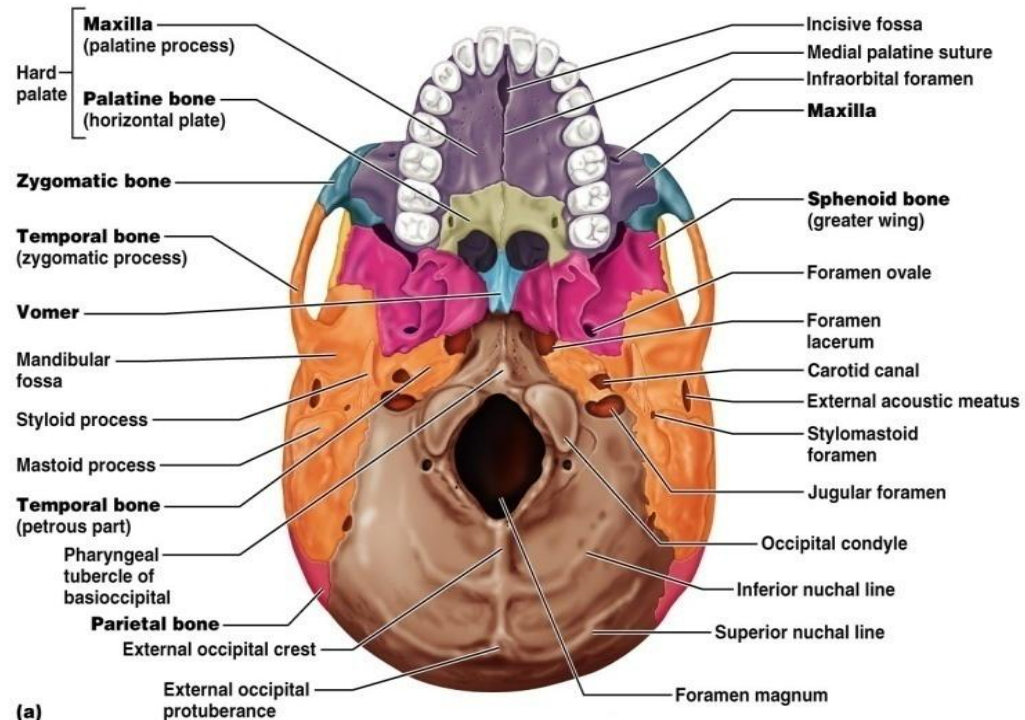
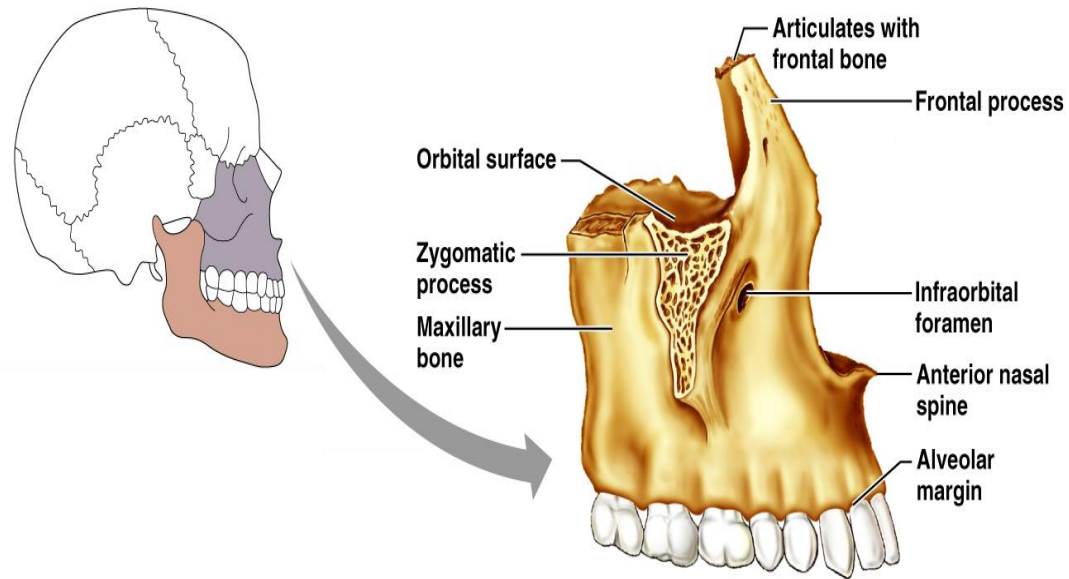
(a) Mandible

Maxillary Bones

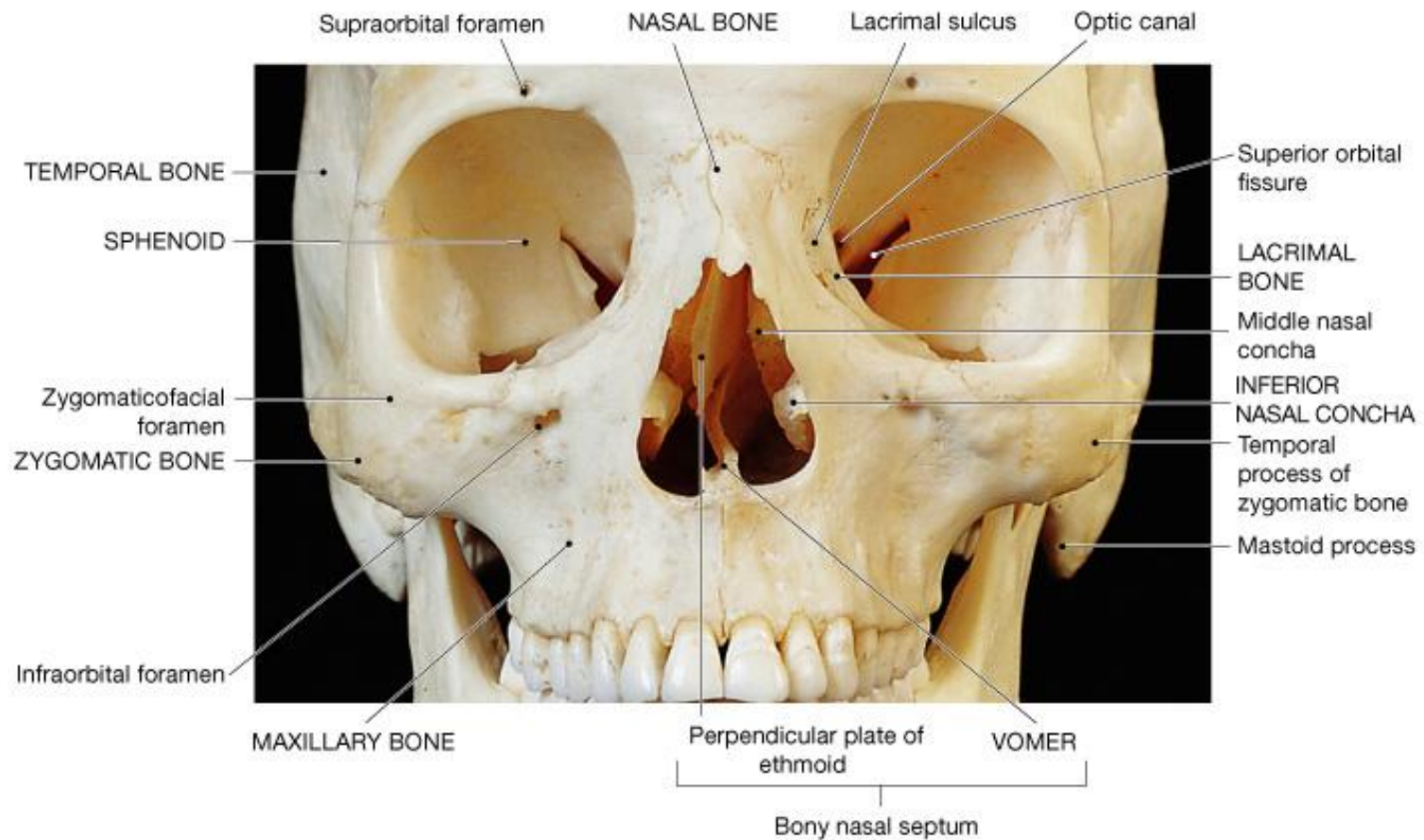
- Medially fused bones that make up the upper jaw and the central portion of the facial skeleton
- Facial keystone bone that articulates with all other facial bones except the mandible
- Holds the upper teeth
- Palatine process fuses to form hard palate (roof of the mouth)
- Maxillary sinuses - largest of paranasal sinuses

Markings to know:

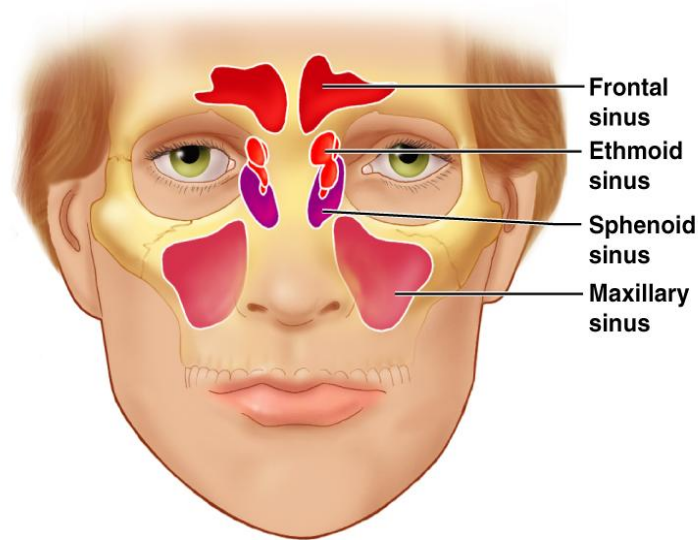
- palatine process
- infraorbital foramen



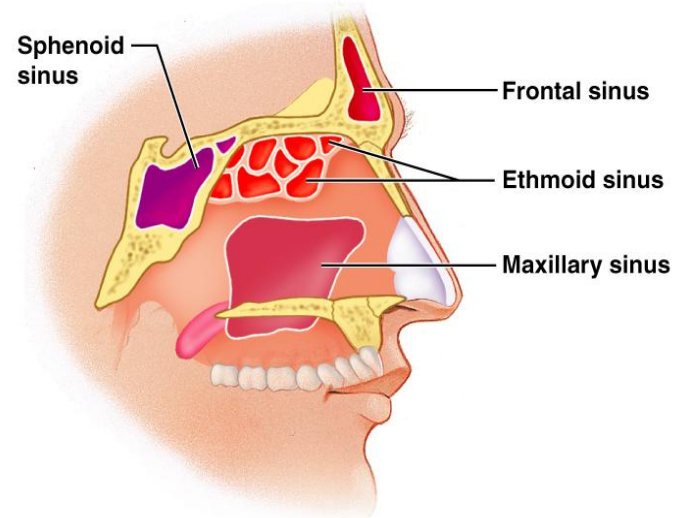
(a)



Paranasal Sinuses



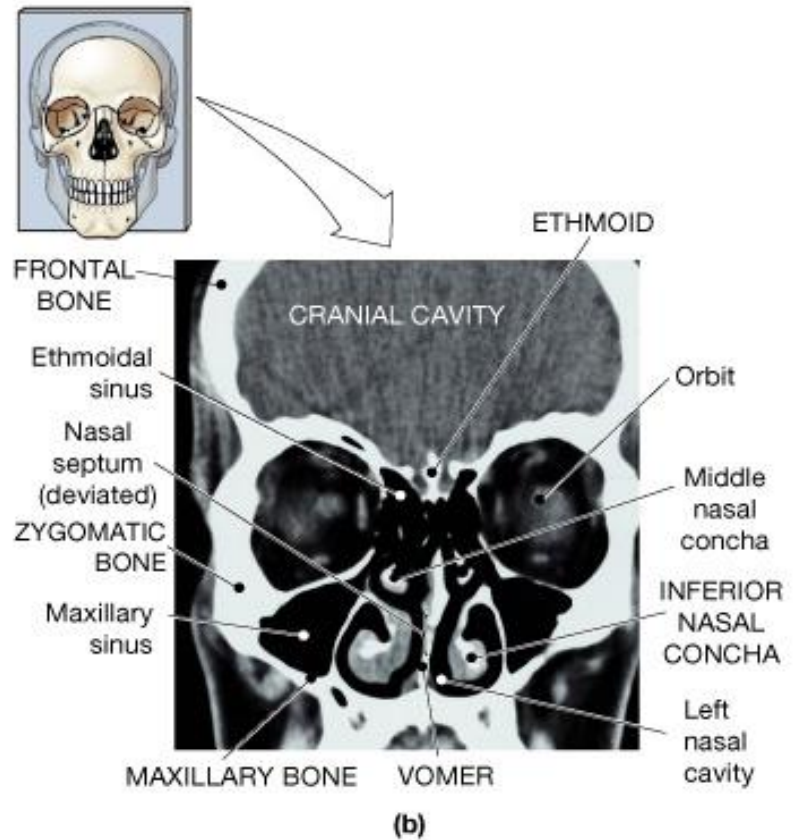
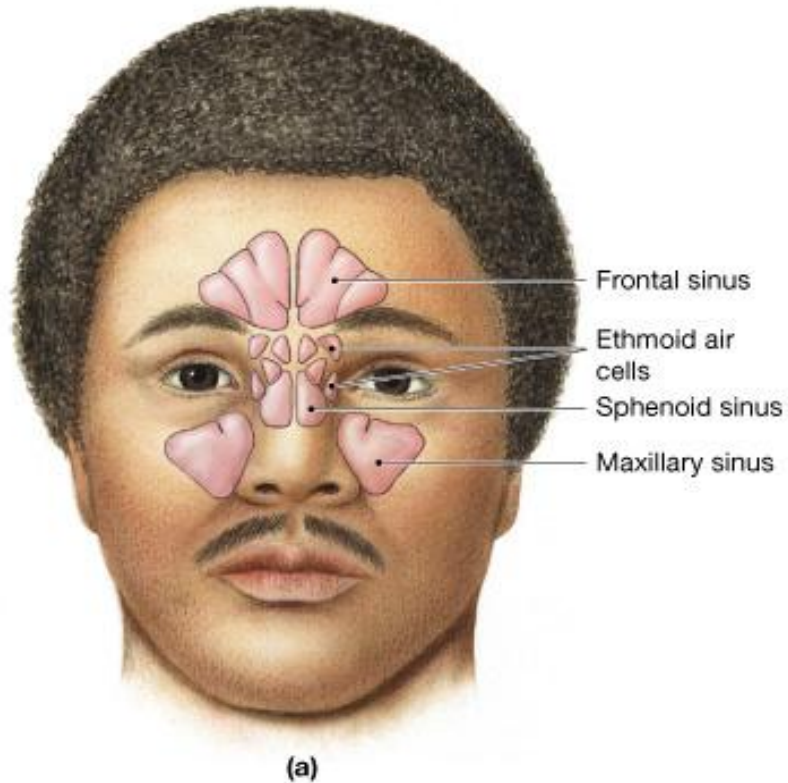
(a)



(b)

- Mucosa-lined, air-filled sacs found in five skull bones - the **frontal, sphenoid, ethmoid, and paired maxillary bones**
- Air enters the paranasal sinuses from the nasal cavity and mucus drains into the nasal cavity from the sinuses
- Sinuses lighten the skull and enhance the resonance of the voice and the mucous membrane moistens, cleans.

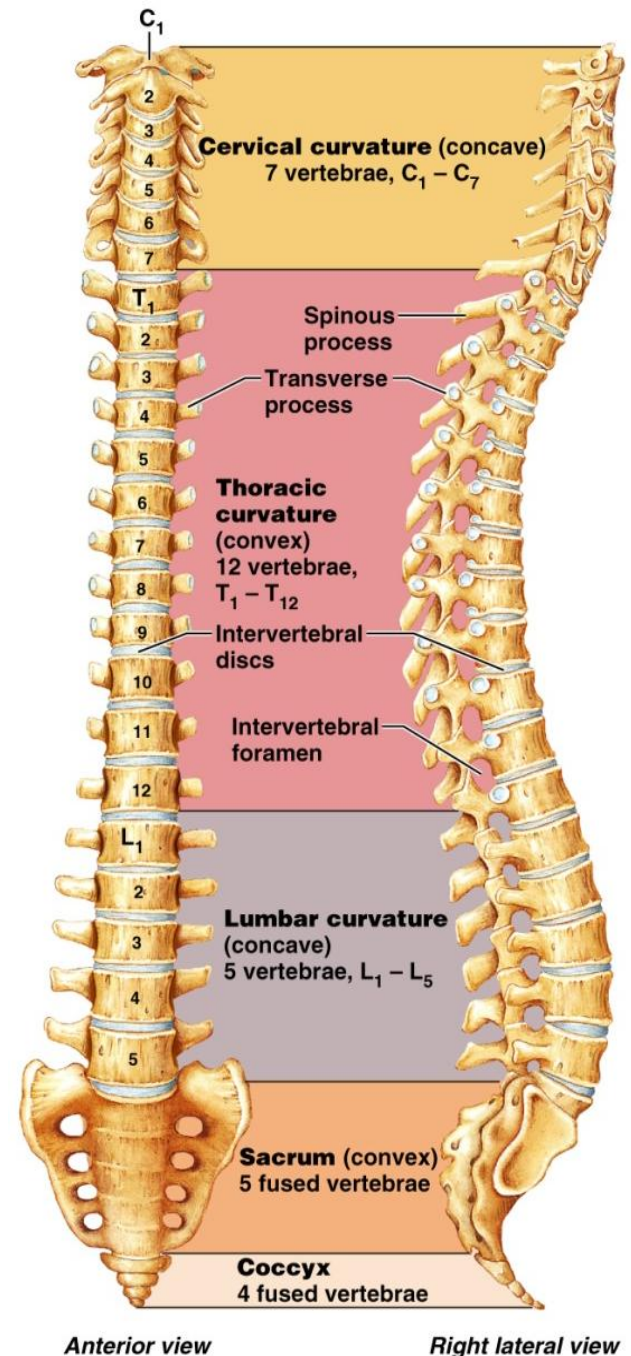
Sinuses



Vertebral Column

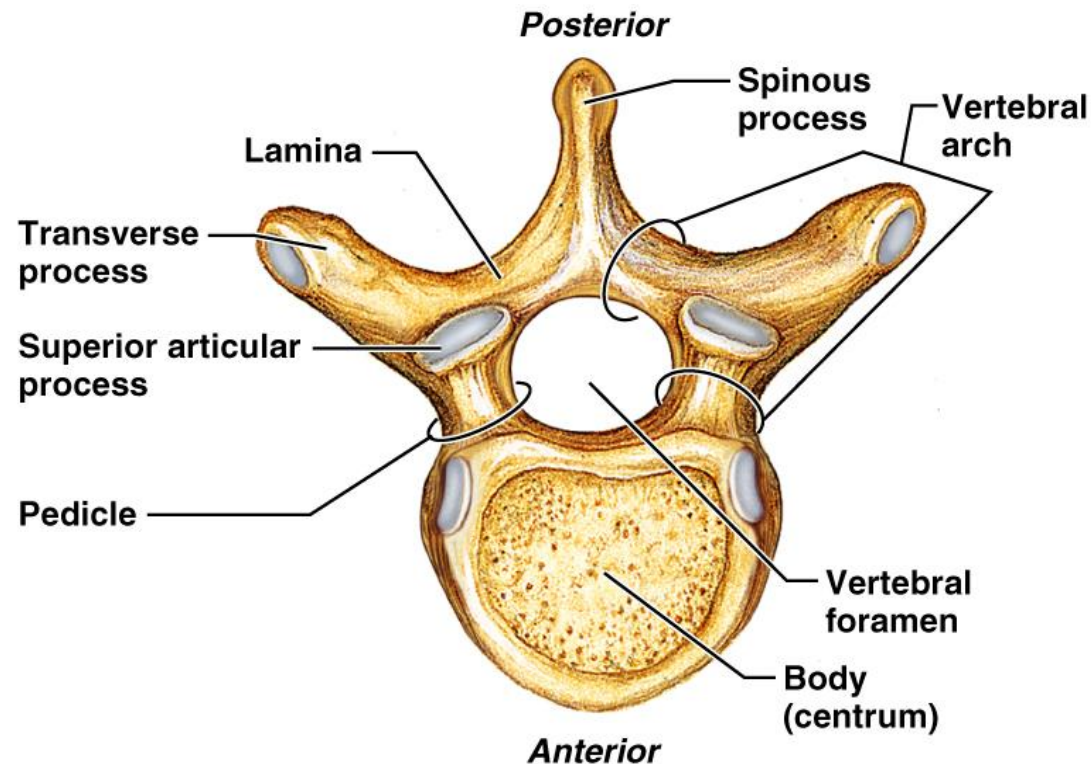
Formed from 26 irregular bones (vertebrae) connected in such a way that a flexible curved structure results

- Cervical vertebrae - 7 bones of the neck
- Thoracic vertebrae - 12 bones of the torso
- Lumbar vertebrae - 5 bones of the lower back
- Sacrum - bone inferior to the lumbar vertebrae that articulates with the hip bones
- Posteriorly concave curves - cervical and lumbar (develop as you hold head up, stand up)
- Posteriorly convex curvatures - thoracic and sacral
- Abnormal spine curvatures include scoliosis (abnormal lateral curve), kyphosis (hunchback), and lordosis (swayback)



General Structure of Vertebrae

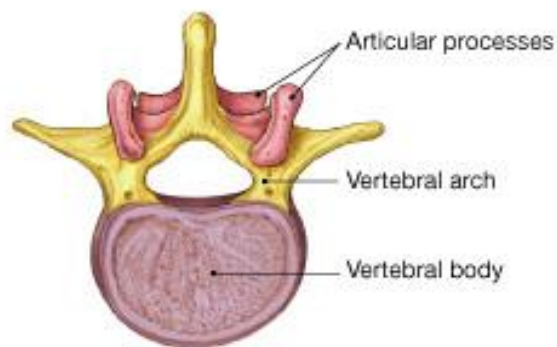
- **Body or centrum** - disc-shaped, weight-bearing region
- **Vertebral arch** - composed of pedicles and laminae that, along with the centrum, enclose the vertebral foramen
- **Vertebral foramina** - make up the vertebral canal through which the spinal cord passes
- **Spinous processes** project posteriorly, and transverse processes project laterally
- **Superior and inferior articular processes** - protrude superiorly and inferiorly from the pedicle-lamina junctions
- **Intervertebral foramen** - lateral openings formed from notched areas on the superior and inferior borders of adjacent pedicles



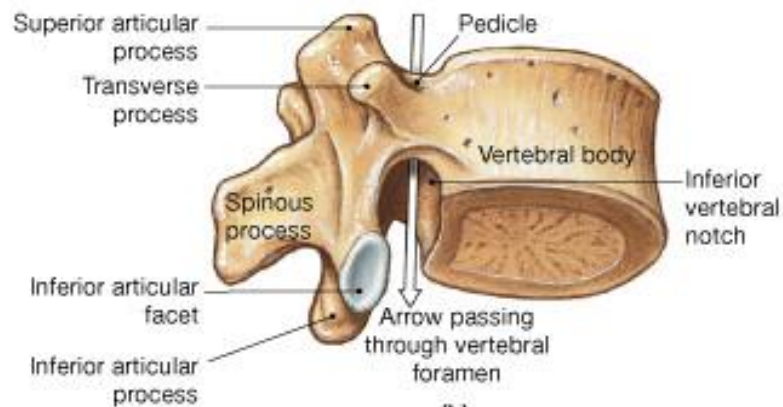
Vertebra

Markings to Know:

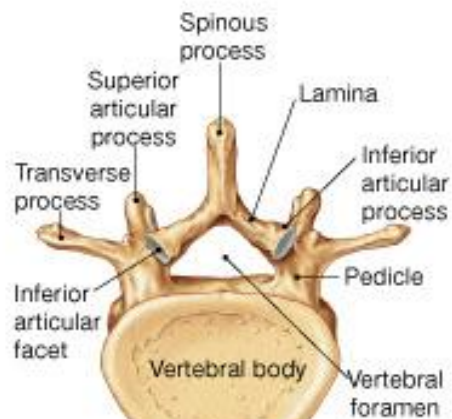
- body
- vertebral foramen
- spinous process
- superior and inferior articular processes
- vertebral arch (lamina and pedicle)
- transverse process
- intervertebral foramen
- transverse foramen (cervical vertebra only)
- dens (axis only)
- sacral foramina and sacral canal (sacrum only)



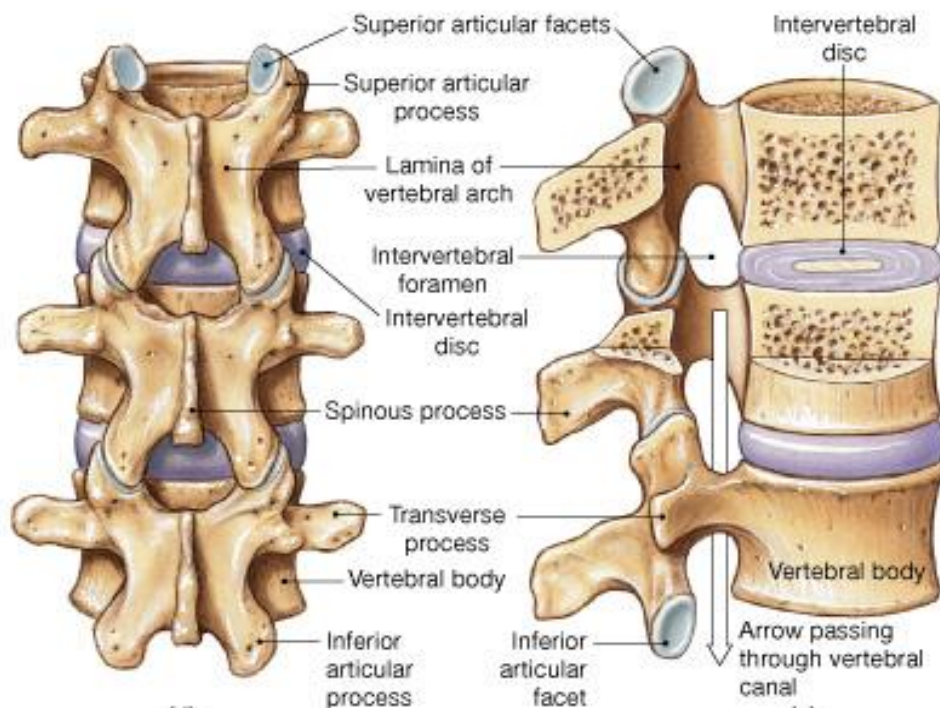
(a)



(b)



(c)



(d)

(e)

Vertebrae

- Bodies get **larger** as you descend (more weight)
- Foramen get **smaller** as you descend (less information in spinal cord)
- Shape of spinous process helps to identify vertebrae from each region:

Regional Characteristics of Vertebrae

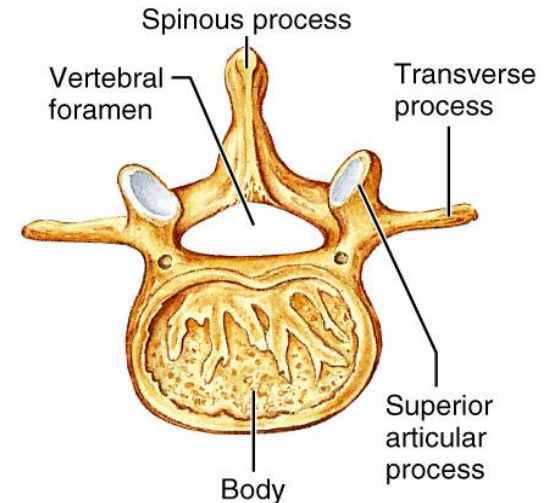
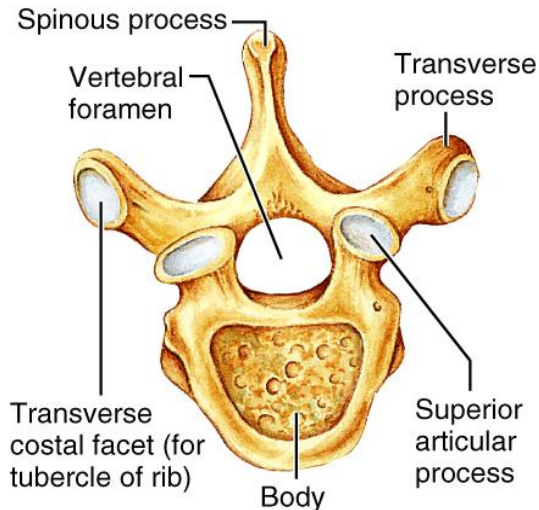
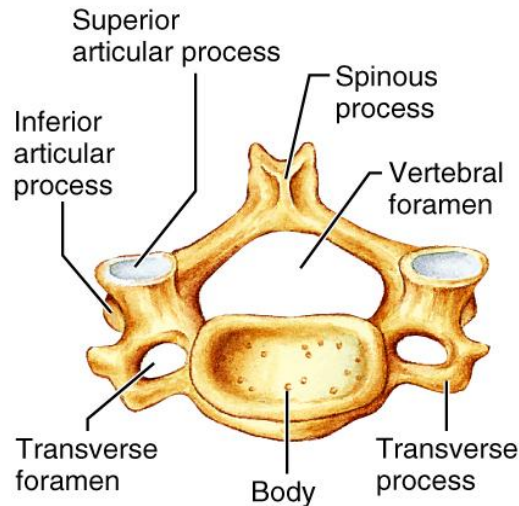
TABLE 7.2 Regional Characteristics of Cervical, Thoracic, and Lumbar Vertebrae

CERVICAL (3-7)

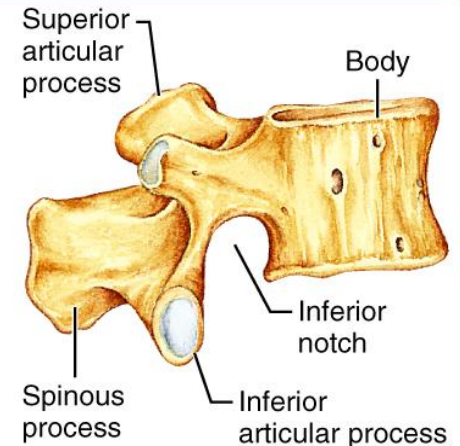
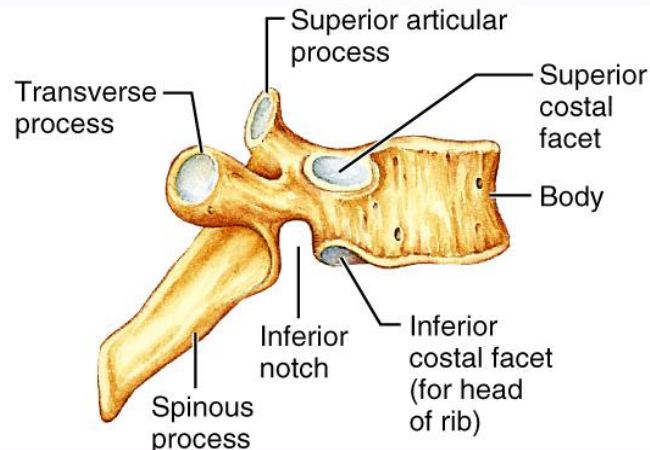
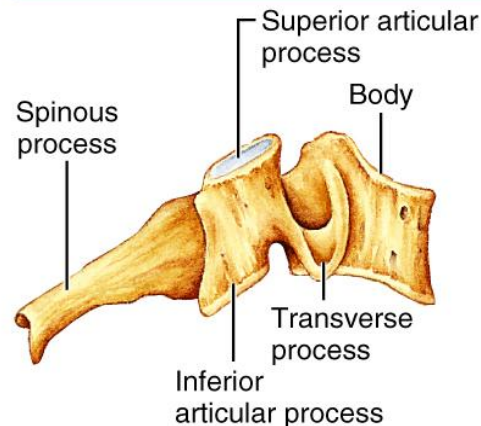
THORACIC

LUMBAR

SUPERIOR VIEW

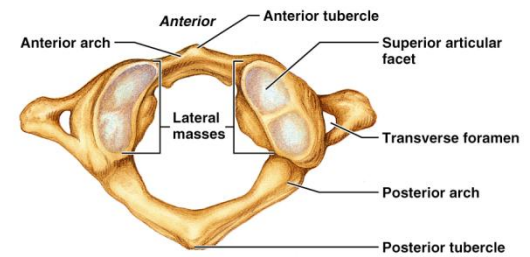
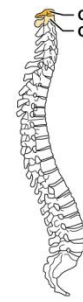

RIGHT LATERAL VIEW

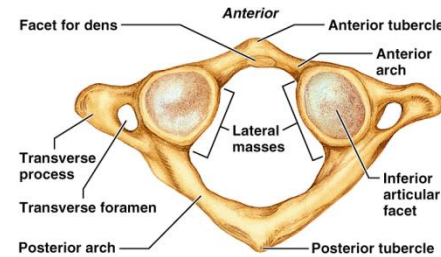


Cervical Vertebrae

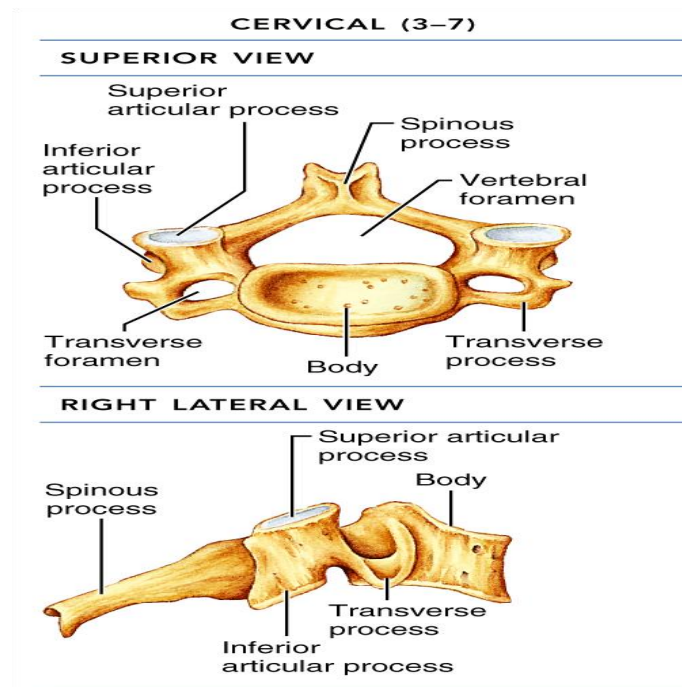
- Seven vertebrae (C_1 - C_7) are the smallest, lightest vertebrae
- C_3 - C_7 are distinguished with an oval body, short spinous processes, and large, triangular vertebral foramina
- Each transverse process contains a transverse foramen
- The atlas has no body and no spinous process
 - It consists of anterior and posterior arches, and two lateral masses
 - The superior surfaces of lateral masses articulate with the occipital condyles
- The axis has a body, spine, and vertebral arches as do other cervical vertebrae
 - Unique to the axis is the dens, or odontoid process, which projects superiorly from the body and is cradled in the anterior arch of the atlas
 - The dens is a pivot for the rotation of the atlas



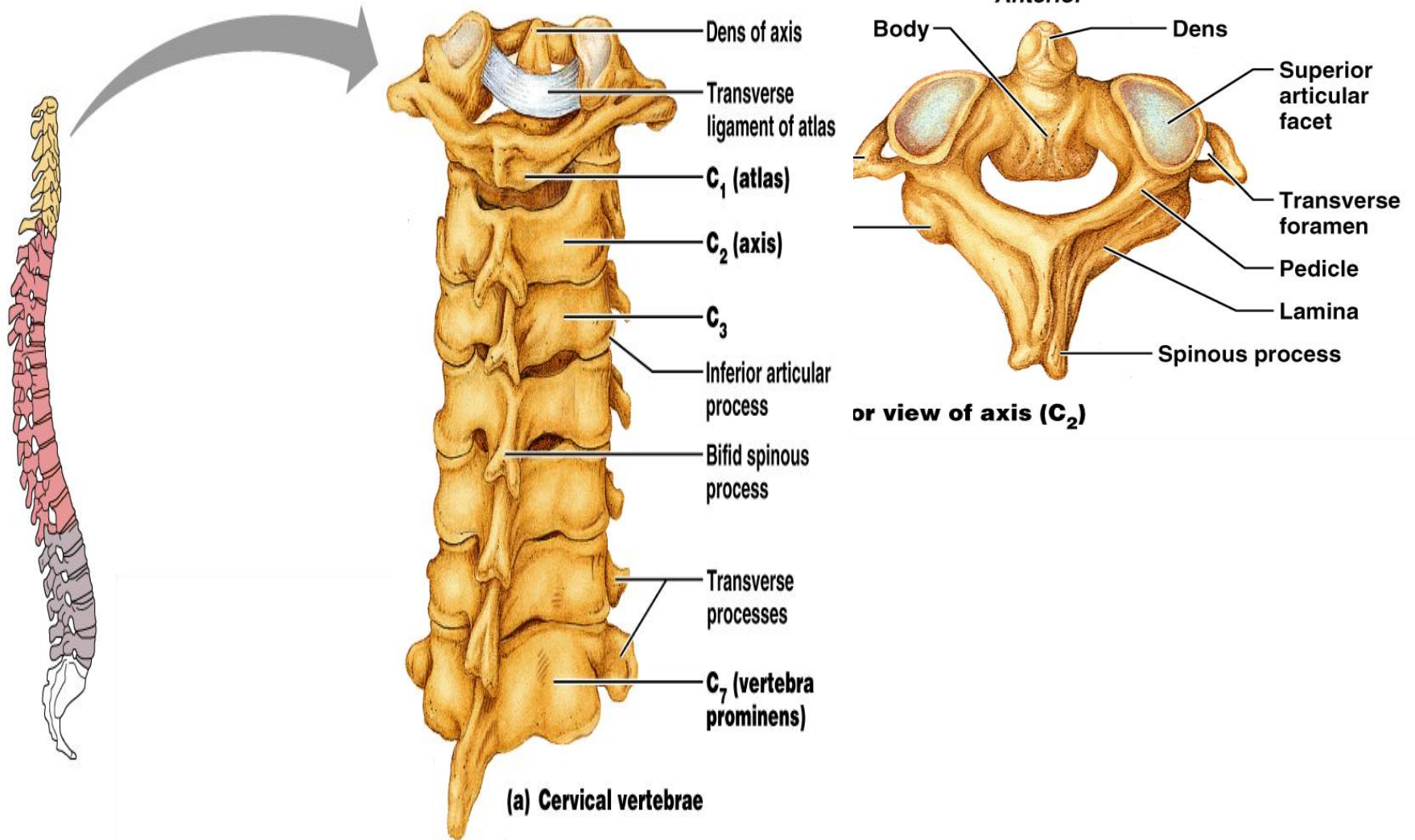
(a) Superior view of atlas (C_1)



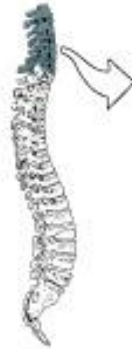(b) Inferior view of atlas (C_1)



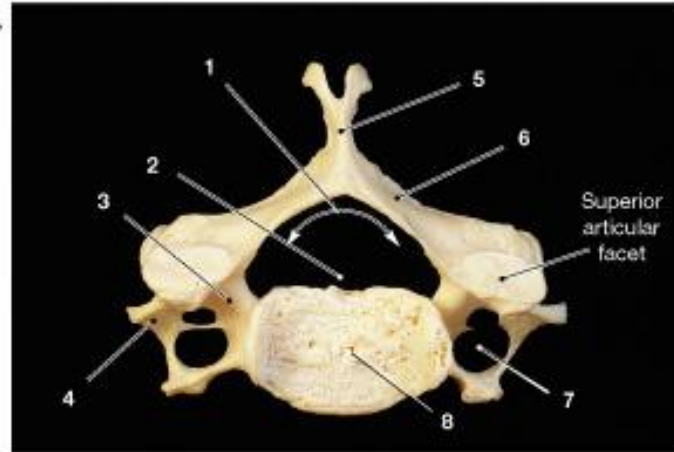
Cervical Vertebrae: The Axis



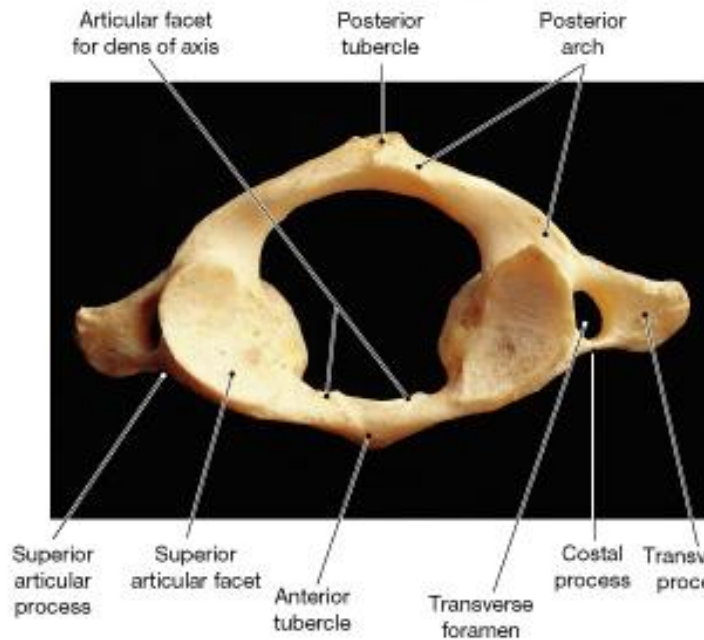
Cervical vertebrae (7)



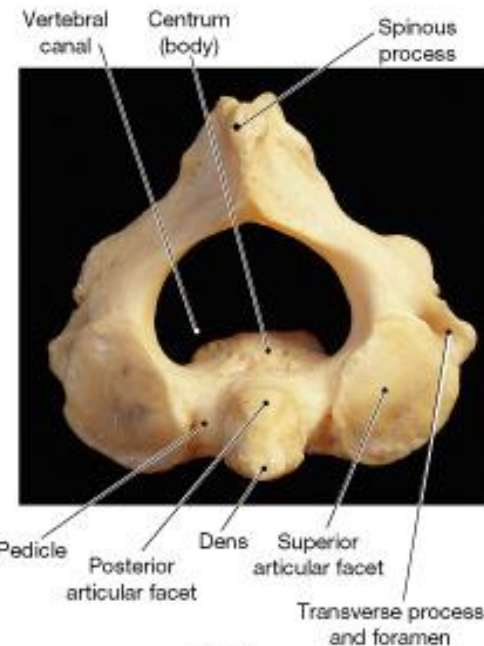
body	transverse foramen
lamina	transverse process
pedicle	vertebral arch
spinous process	vertebral foramen



(a) Typical cervical vertebra



(b) Atlas

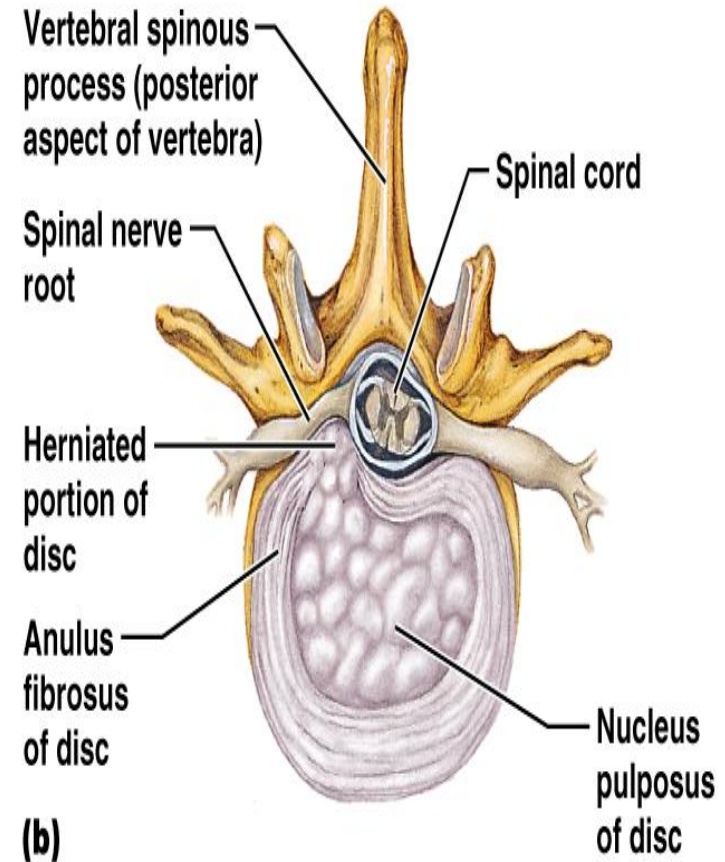


(c) Axis

Vertebral Column: Intervertebral Discs

Cushion-like pad
composed of two
parts

- Nucleus pulposus - inner gelatinous nucleus that gives the disc its elasticity and compressibility
- Annulus fibrosus - surrounds the nucleus pulposus with a collar composed of collagen and fibrocartilage



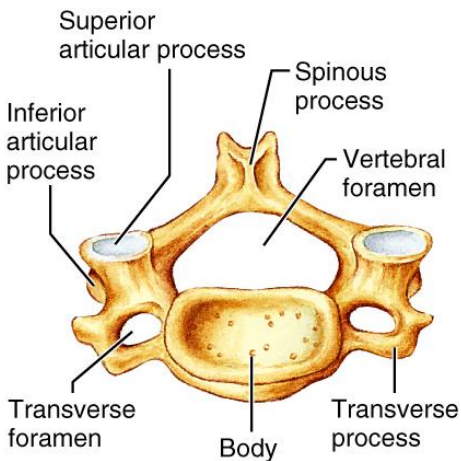
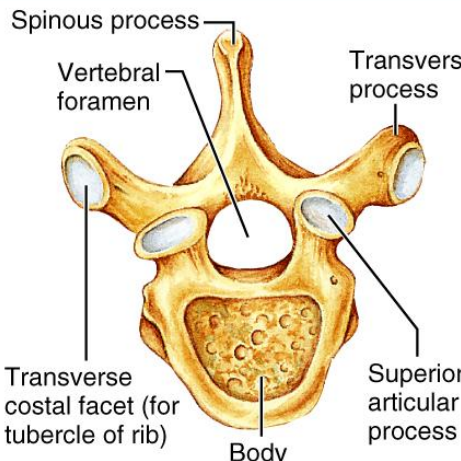
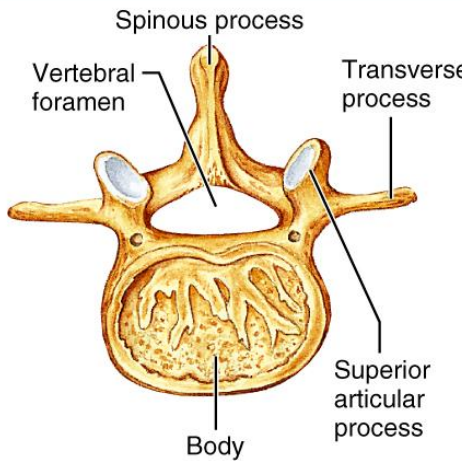
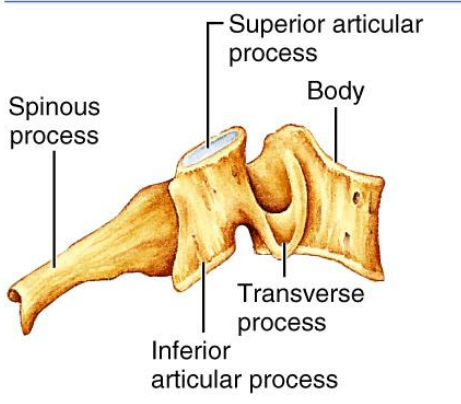
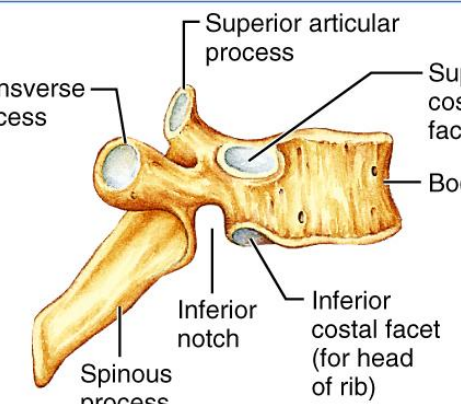
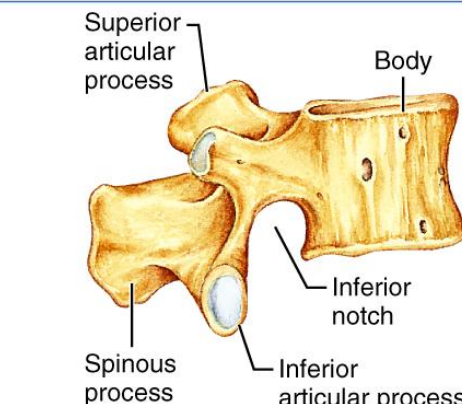
Regional Characteristics of Vertebrae

TABLE 7.2 Regional Characteristics of Cervical, Thoracic, and Lumbar Vertebrae

CHARACTERISTIC	CERVICAL (3–7)	THORACIC	LUMBAR
Body	Small, wide side to side	Larger than cervical; heart shaped; bears two costal facets	Massive; kidney shaped
Spinous process	Short; bifid; projects directly posteriorly	Long; sharp; projects inferiorly	Short; blunt; projects directly posteriorly
Vertebral foramen	Triangular	Circular	Triangular
Transverse processes	Contain foramina	Bear facets for ribs (except T ₁₁ and T ₁₂)	Thin and tapered
Superior and inferior articulating processes	Superior facets directed superoposteriorly	Superior facets directed posteriorly	Superior facets directed posteromedially (or medially)
	Inferior facets directed inferoanteriorly	Inferior facets directed anteriorly	Inferior facets directed anterolaterally (or laterally)
Movements allowed	Flexion and extension; lateral flexion; rotation; the spine region with the greatest range of movement	Rotation; lateral flexion possible but limited by ribs; flexion and extension prevented	Flexion and extension; some lateral flexion; rotation prevented

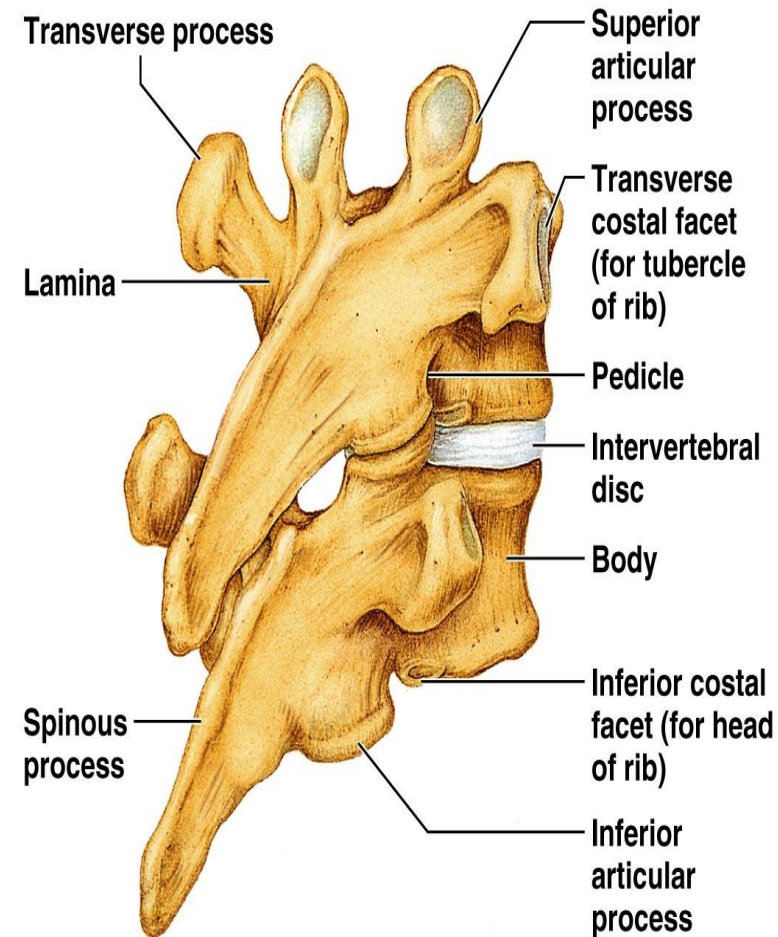
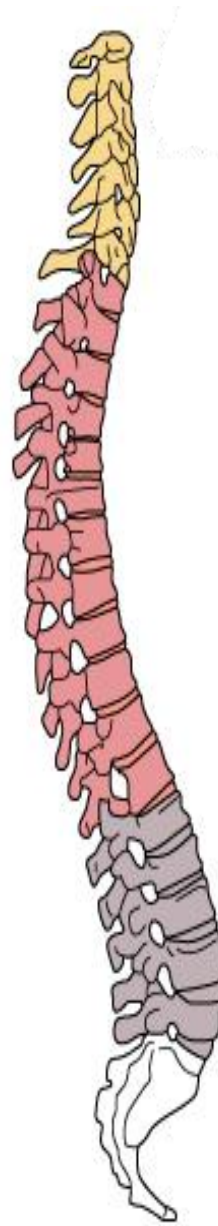
Regional Characteristics of Vertebrae

TABLE 7.2 Regional Characteristics of Cervical, Thoracic, and Lumbar Vertebrae

CERVICAL (3-7)	THORACIC	LUMBAR
SUPERIOR VIEW		
 <p>Superior articular process</p> <p>Spinous process</p> <p>Vertebral foramen</p> <p>Inferior articular process</p> <p>Transverse foramen</p> <p>Body</p> <p>Transverse process</p>	 <p>Spinous process</p> <p>Vertebral foramen</p> <p>Transverse process</p> <p>Transverse costal facet (for tubercle of rib)</p> <p>Superior articular process</p> <p>Body</p>	 <p>Spinous process</p> <p>Vertebral foramen</p> <p>Transverse process</p> <p>Superior articular process</p> <p>Body</p>
RIGHT LATERAL VIEW		
 <p>Superior articular process</p> <p>Spinous process</p> <p>Body</p> <p>Inferior articular process</p> <p>Transverse process</p>	 <p>Superior articular process</p> <p>Transverse process</p> <p>Superior costal facet</p> <p>Body</p> <p>Inferior notch</p> <p>Inferior costal facet (for head of rib)</p> <p>Spinous process</p>	 <p>Superior articular process</p> <p>Spinous process</p> <p>Body</p> <p>Inferior notch</p> <p>Inferior articular process</p>

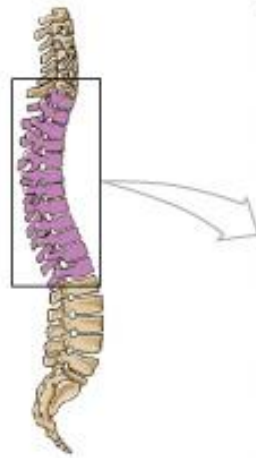Thoracic Vertebrae

- There are twelve vertebrae (T_1 - T_{12}) all of which articulate with ribs
- Major markings include two facets and two demifacets on the heart-shaped body, the circular vertebral foramen, transverse processes, and a long spinous process
- The location of the articulate facets prevents flexion and extension, but allows rotation of this area of the spine

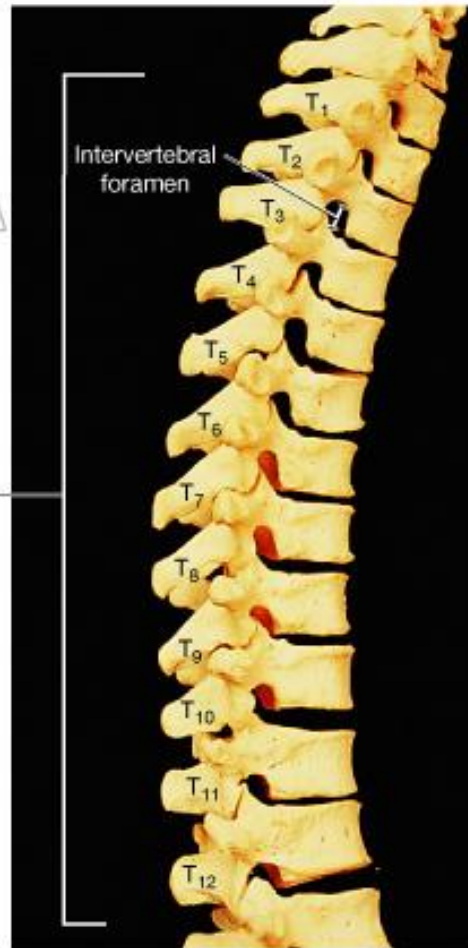

(b) Thoracic vertebrae

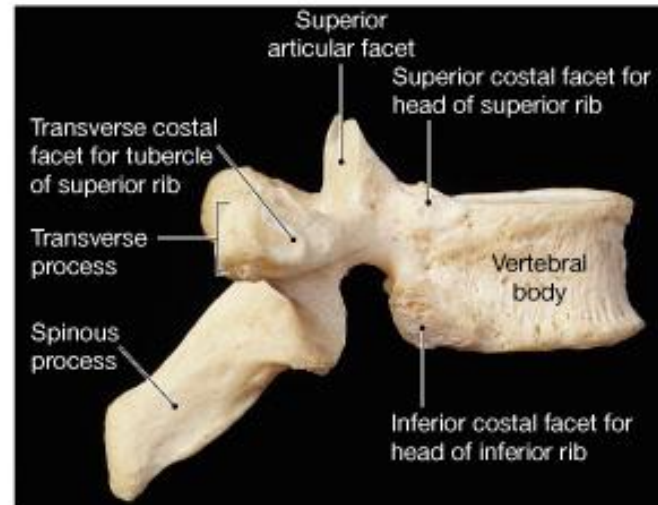
Thoracic vertebrae (12)



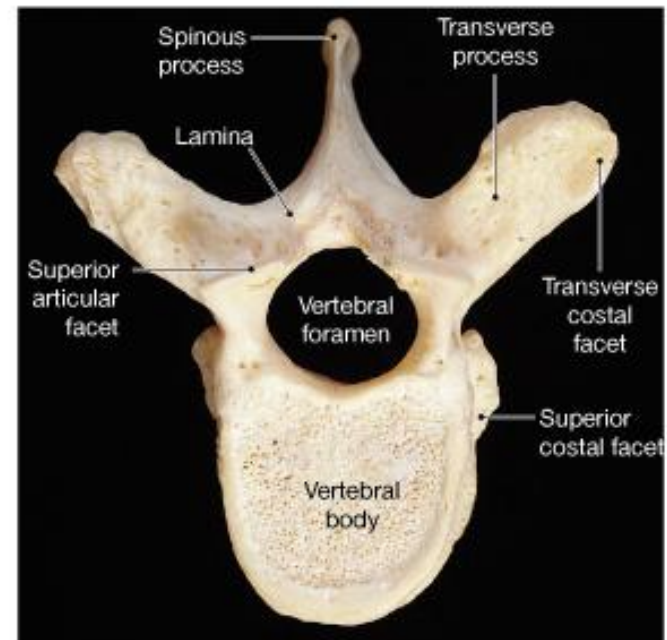
Thoracic
vertebrae
(T₁-T₁₂)



(a) Thoracic vertebrae, lateral view



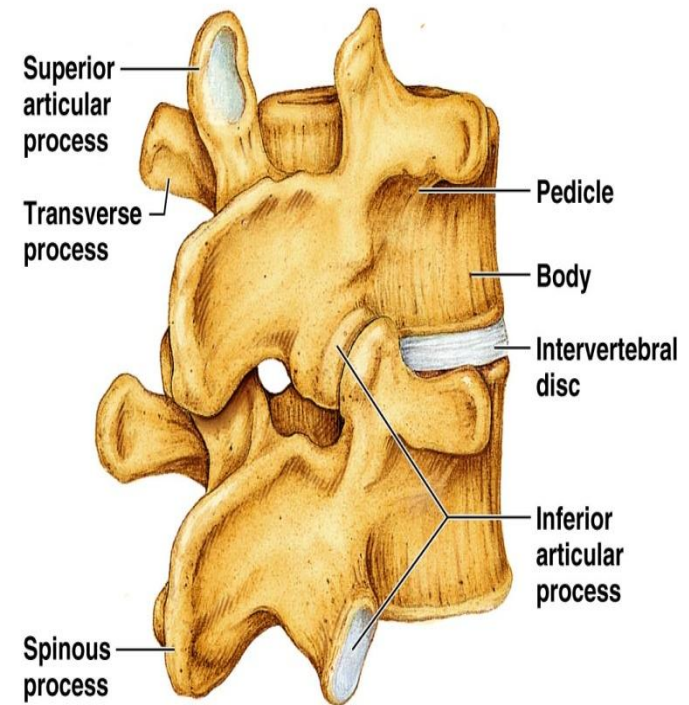
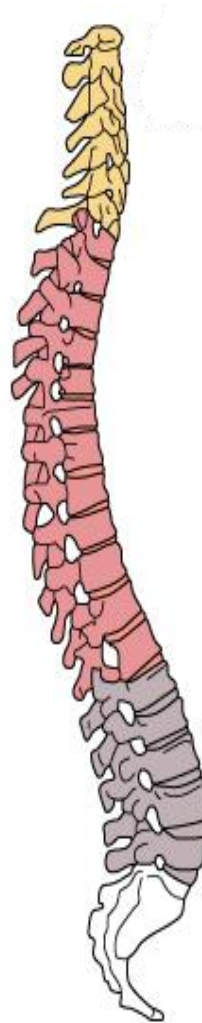
(b)



(c)

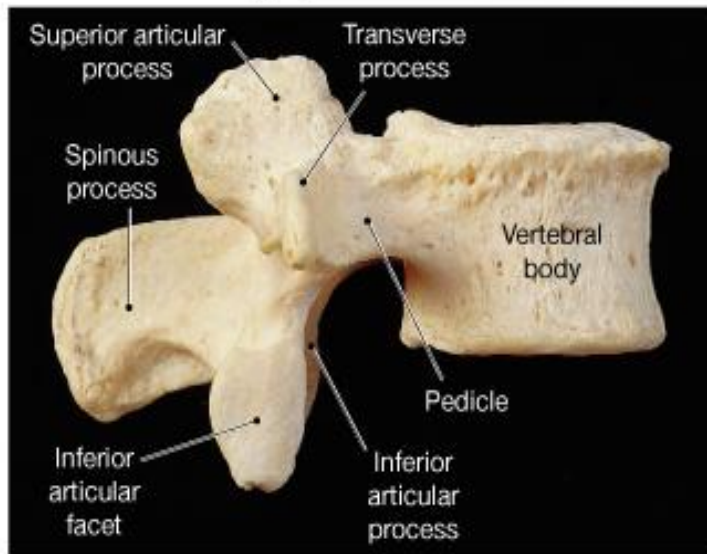
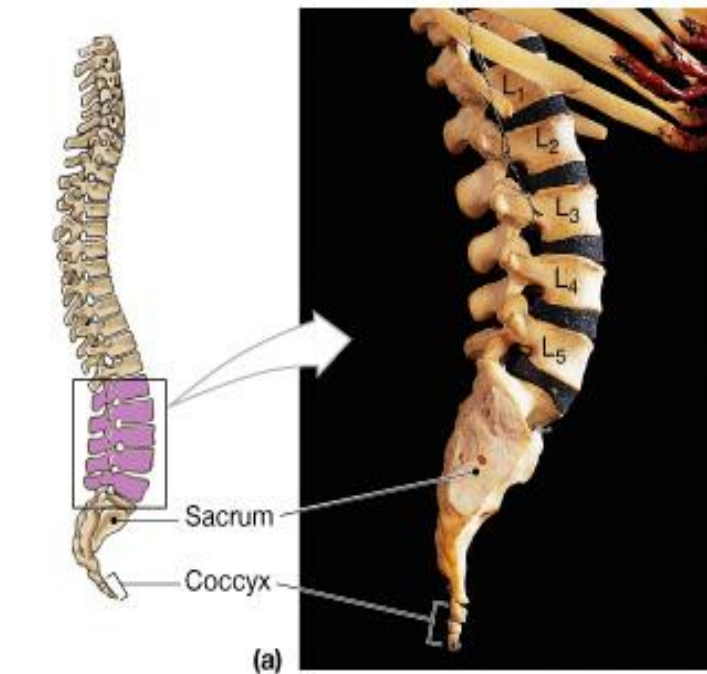
Lumbar Vertebrae

- The five lumbar vertebrae (L_1 - L_5) are located in the small of the back and have an enhanced weight-bearing function
- They have short, thick pedicles and laminae, flat hatchet-shaped spinous processes, and a triangular-shaped vertebral foramen
- Orientation of articular facets locks the lumbar vertebrae together to provide stability

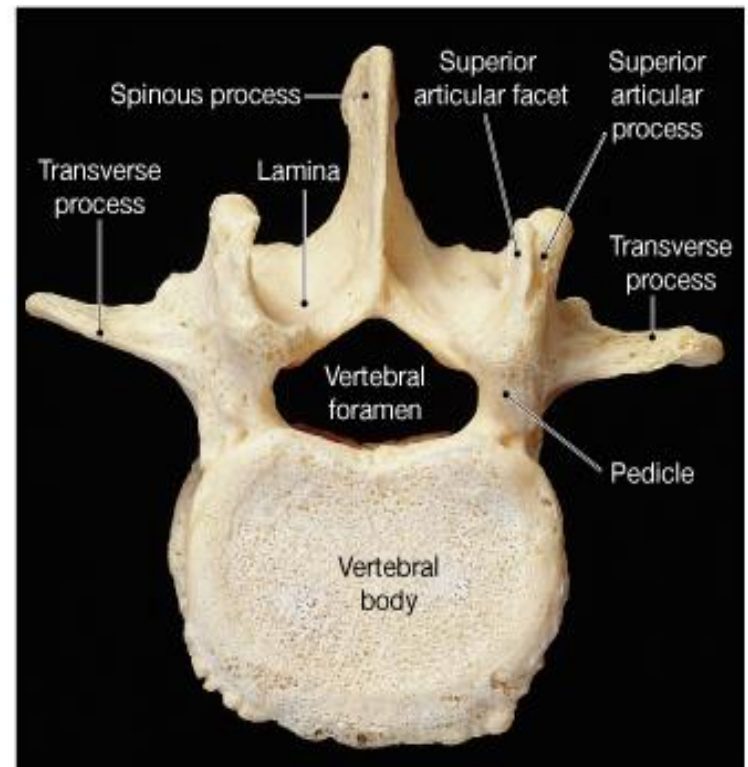


(c) Lumbar vertebrae

Lumbar vertebrae (5)



(b) Lateral view



(c) Superior view

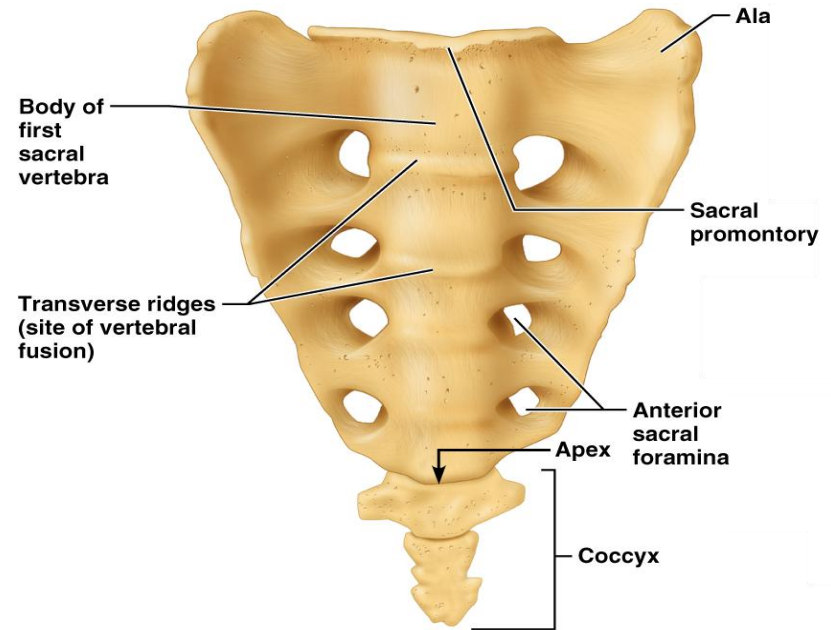
Sacrum

Sacrum

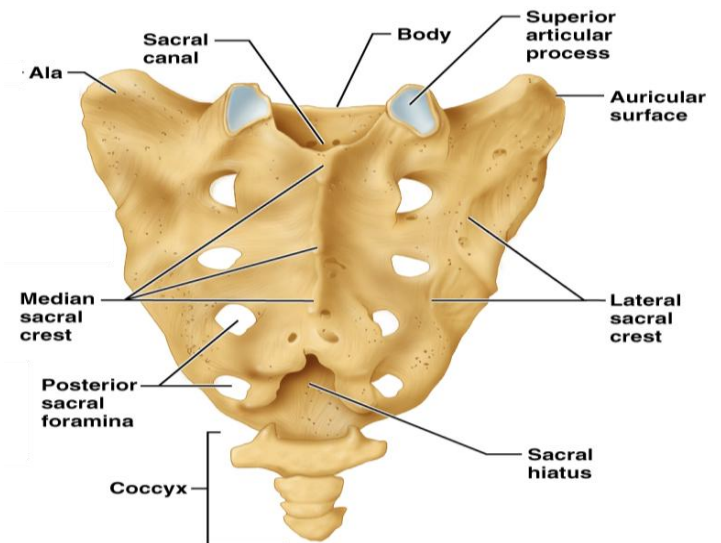
- Consists of five fused vertebrae (S_1 - S_5), which shape the posterior wall of the pelvis
- It articulates with L_5 superiorly, and with the auricular surfaces of the hip bones
- Major markings include the sacral promontory, transverse lines, alae, dorsal sacral foramina, sacral canal, and sacral hiatus

Coccyx (Tailbone)

- The coccyx is made up of four (in some cases three to five) fused vertebrae that articulate superiorly with the sacrum

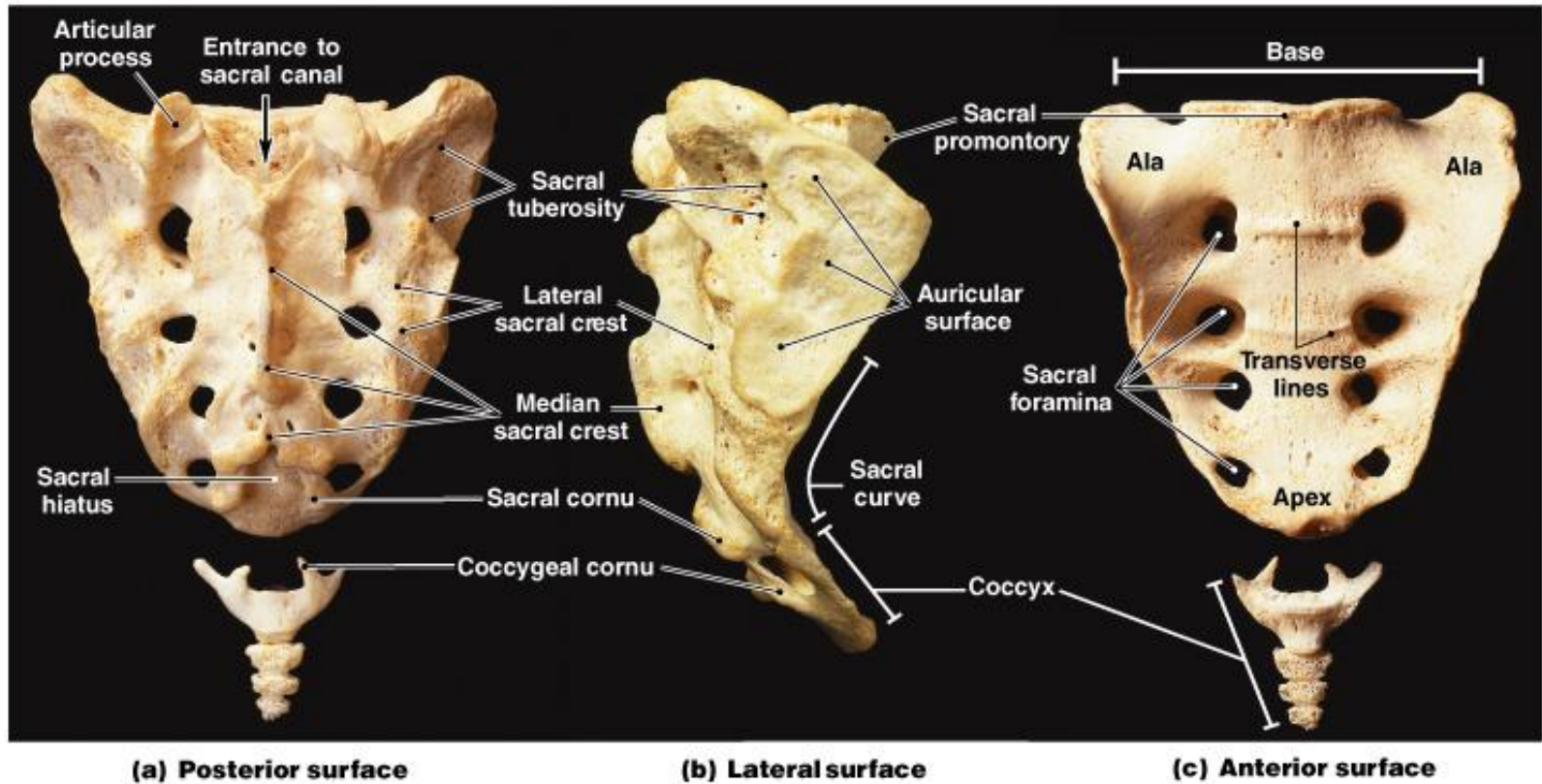


(a) Anterior view



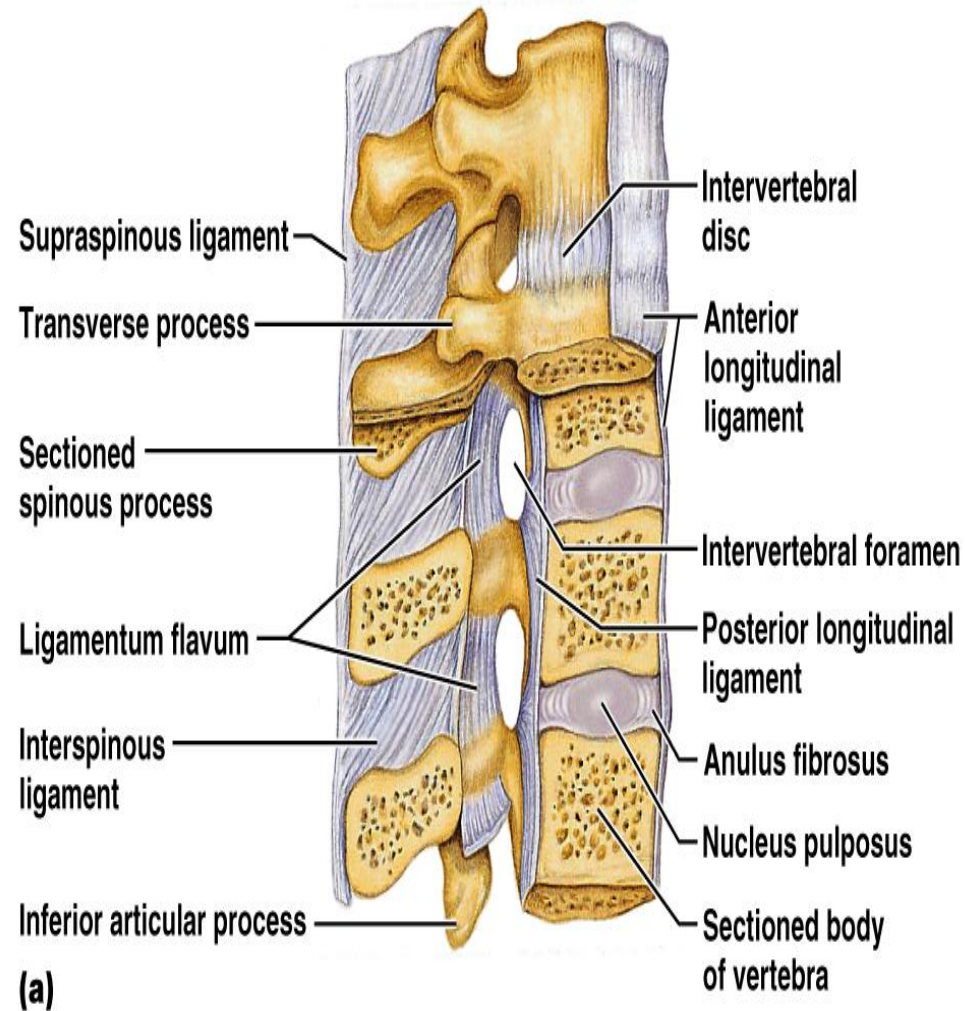
(b) Posterior view

Sacrum and Coccyx



Vertebral Column: Ligaments

- Anterior and posterior longitudinal ligaments - continuous bands down the front and back of the spine from the neck to the sacrum
- Short ligaments connect adjoining vertebrae together



Bony Thorax (Thoracic Cage)

The thoracic cage is composed of the thoracic vertebrae dorsally, the ribs laterally, and the sternum and costal cartilages anteriorly

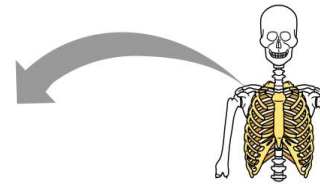
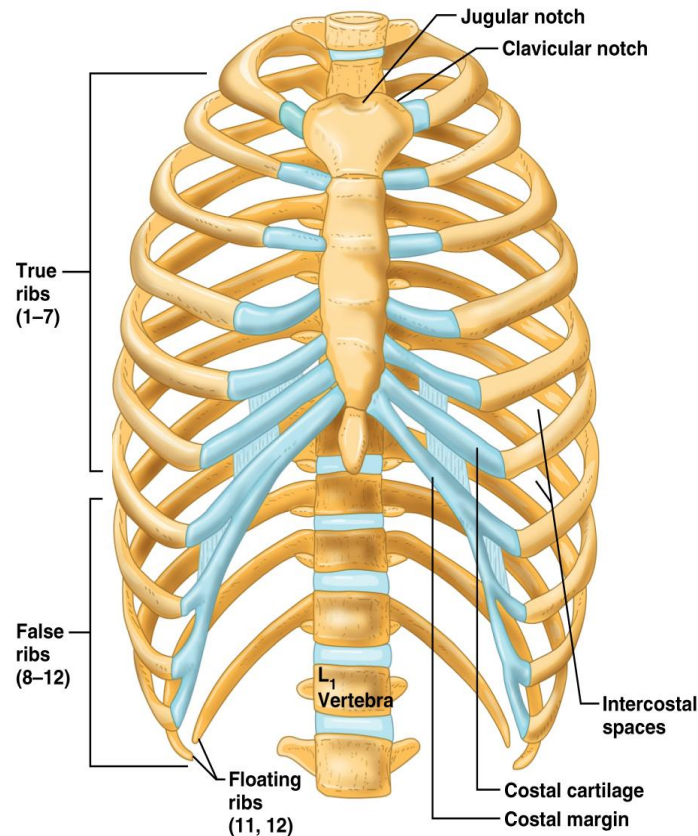
Sternum (Breastbone)

Sternum:

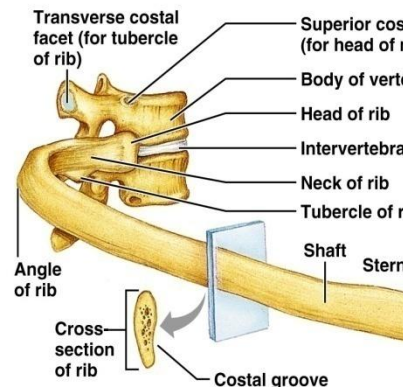
- A dagger-shaped, flat bone that lies in the anterior midline of the thorax
- Results from the fusion of three bones - the superior manubrium, the body, and the inferior xiphoid process
- Anatomical landmarks include the jugular (suprasternal) notch, the sternal angle, and the xiphisternal joint

Ribs

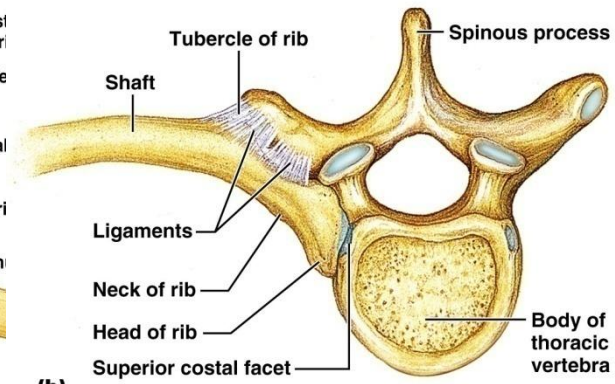
- There are twelve pair of ribs forming the flaring sides of the thoracic cage. total = 24
- All ribs attach posteriorly to the thoracic vertebrae
- The superior 7 pair (true) attach directly to the sternum via costal cartilages
- Ribs 8-10 (false) attach indirectly to the sternum via costal cartilage
- Ribs 11-12 (floating) have no anterior attachment



(a)



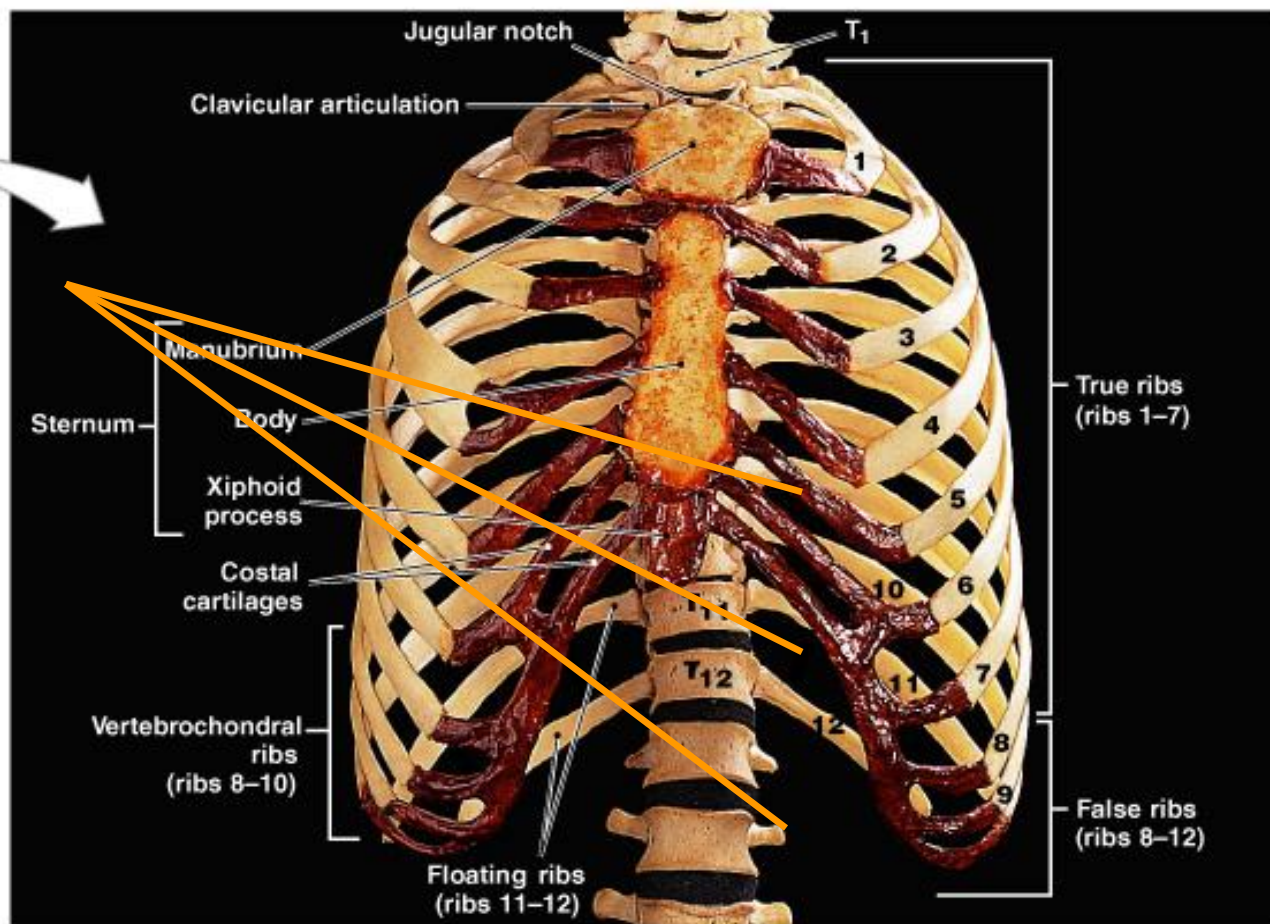
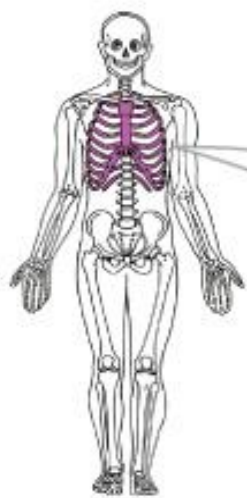
(a)



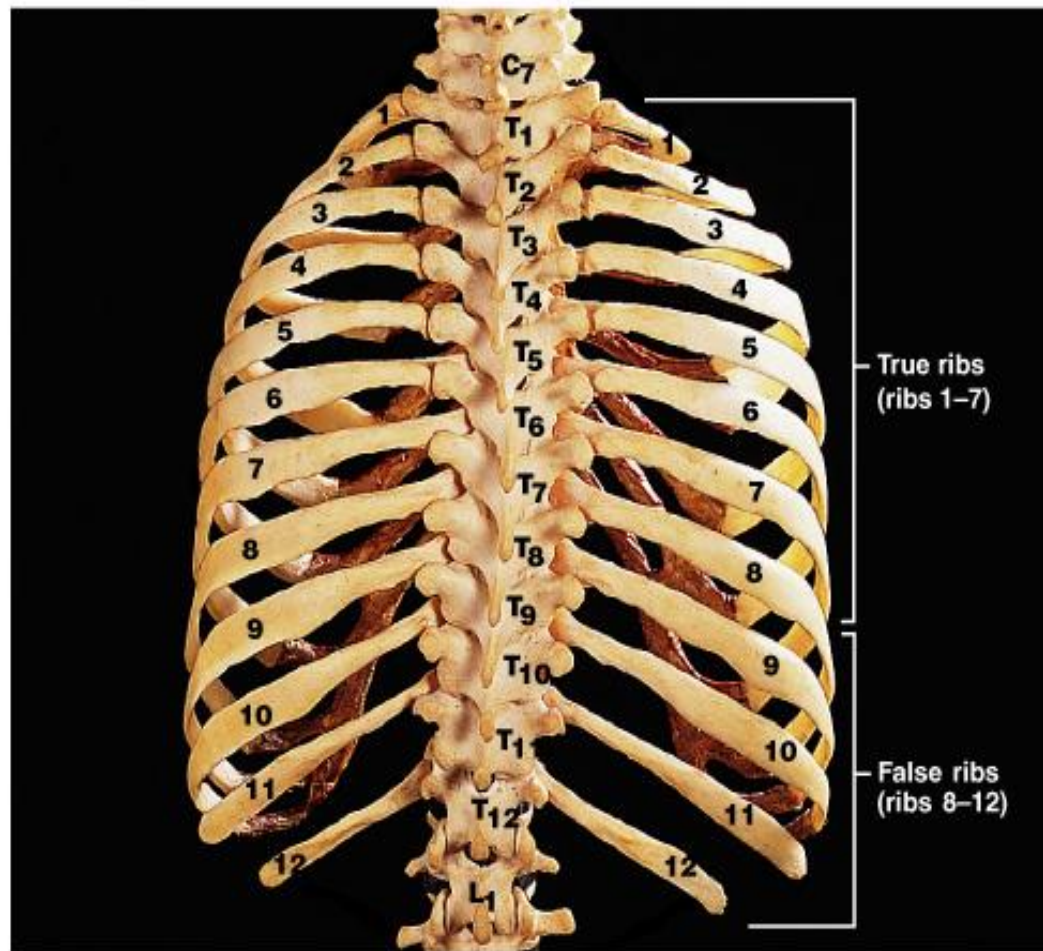
(b)

Ribs and Sternum

- parts of a rib - head (capitulum), neck, body, tubercle

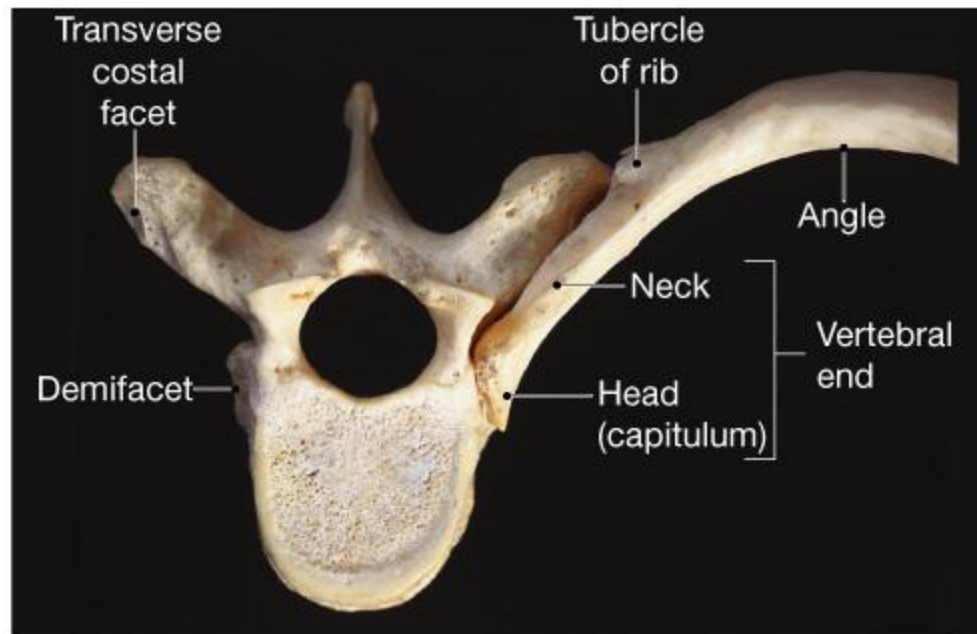


(a) Anterior view

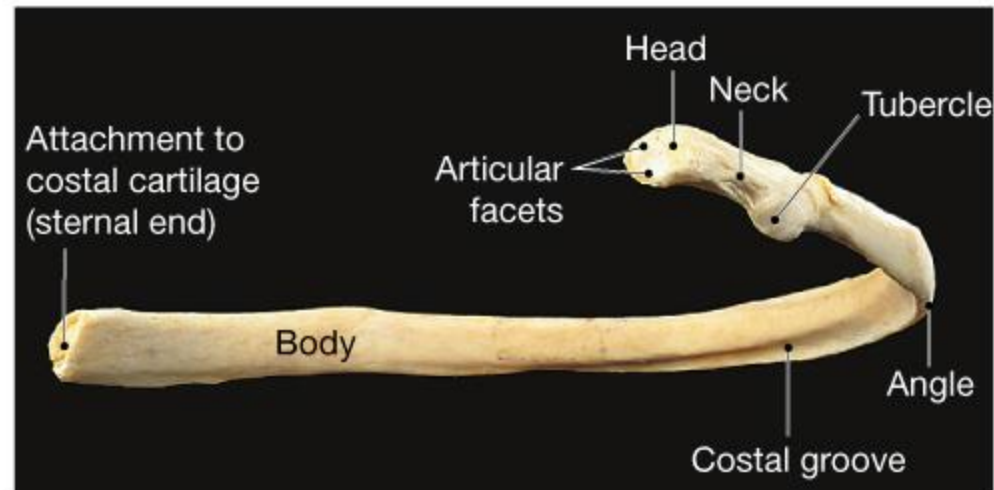


(b) Posterior view

Ribs (24)



(a) Superior view

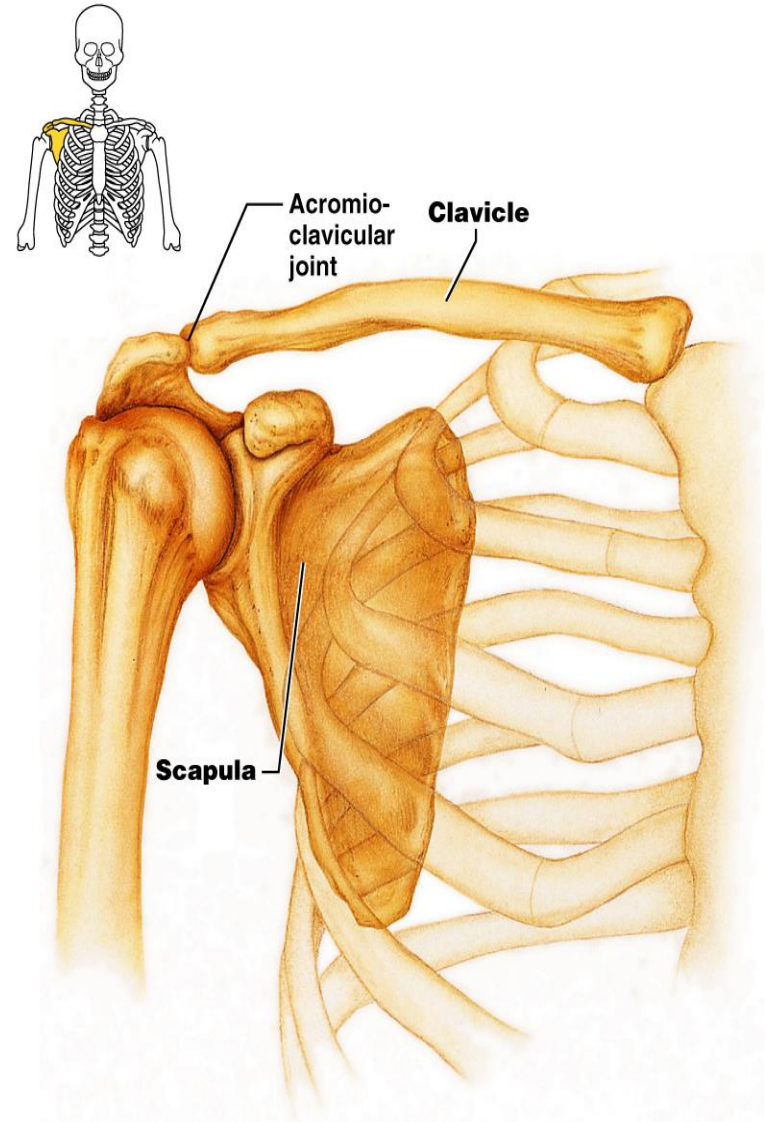


(b) Posterior view

Appendicular Skeleton

The appendicular skeleton is made up of the bones of the limbs and their girdles

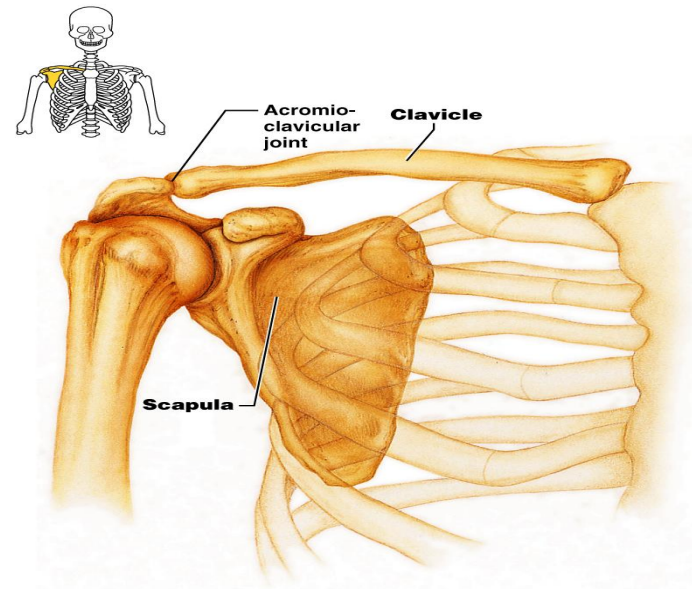
- Pectoral girdles attach the upper limbs to the body trunk
- Pelvic girdle secures the lower limbs
- The pectoral girdles consist of the anterior clavicles and the posterior scapulae
- They attach the upper limbs to the axial skeleton in a manner that allows for maximum movement
- They provide attachment points for muscles that move the upper limbs



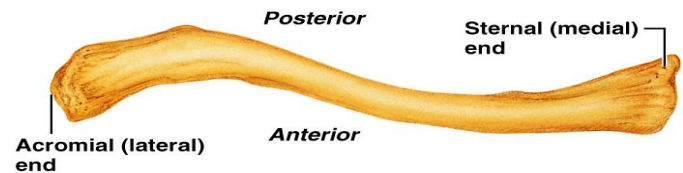
(a) Articulated pectoral girdle

Clavicles (Collarbones)

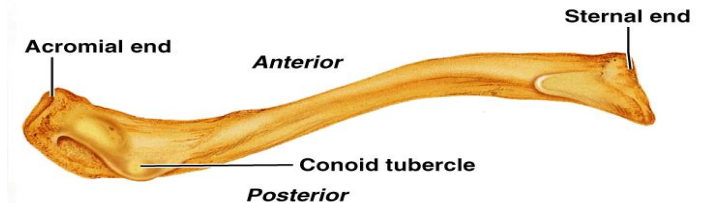
- Slender, doubly curved long bones lying across the superior thorax
- The acromial (lateral) end articulates with the scapula, and the sternal (medial) end articulates with the sternum
- Provide attachment points for numerous muscles, and act as braces to hold the scapulae and arms out laterally away from the body



(a) Articulated pectoral girdle



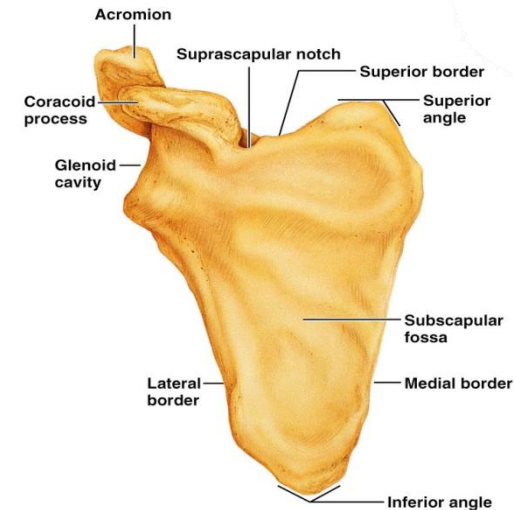
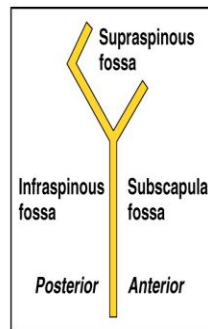
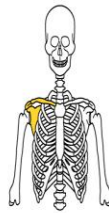
(b) Right clavicle, superior view



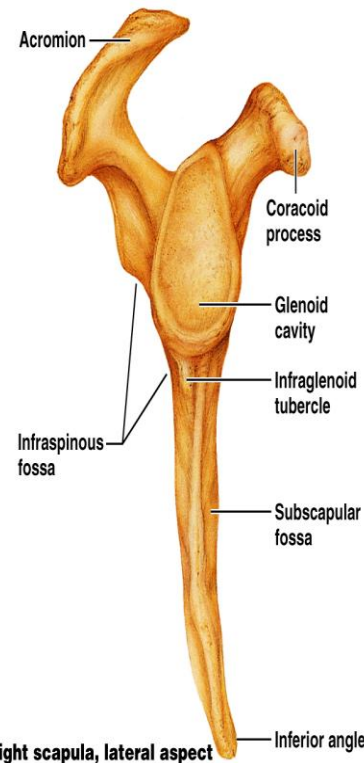
(c) Right clavicle, inferior view

Scapulae (Shoulder Blades)

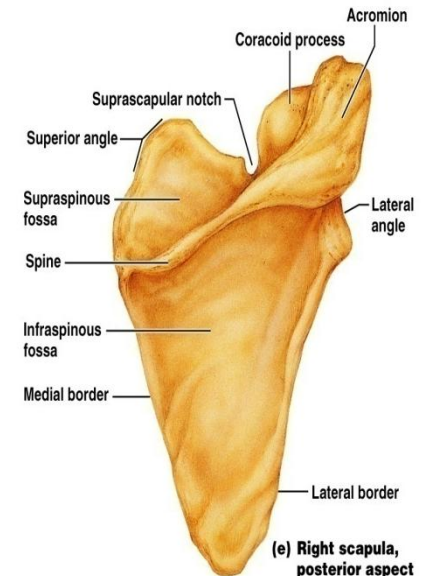
- Triangular, flat bones lying on the dorsal surface of the rib cage, between the second and seventh ribs
- Scapulae have three borders and three angles
- Major markings:
 - inferior and superior angles
 - acromion process
 - coracoid process
 - lateral (axillary) border
 - vertebral (medial) border
 - superior border
 - spine
 - supraspinous and infraspinous fossa
 - glenoid fossa (cavity)



(d) Right scapula, anterior aspect



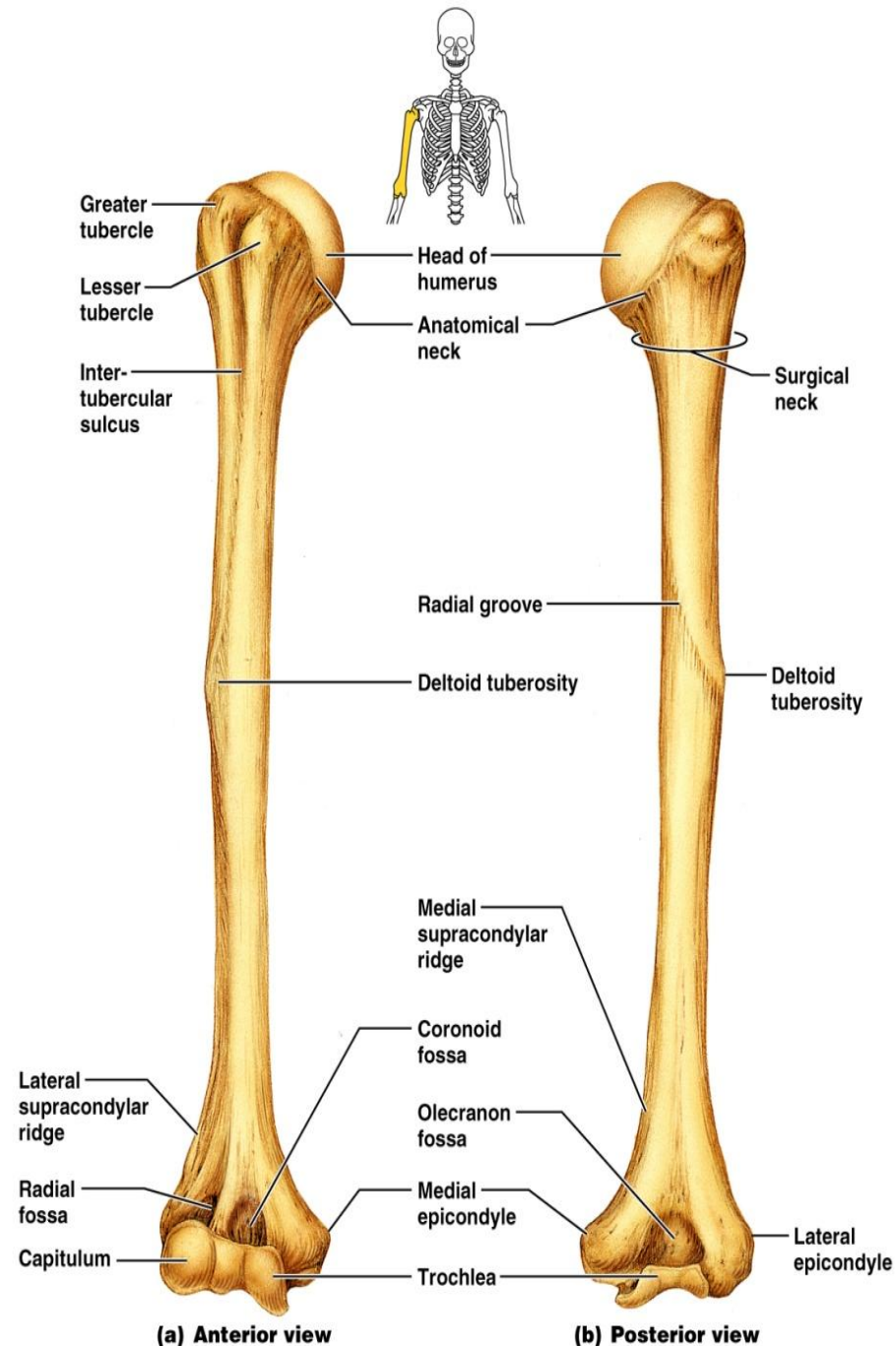
(f) Right scapula, lateral aspect



(e) Right scapula, posterior aspect

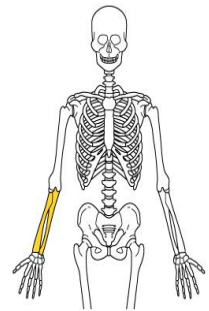
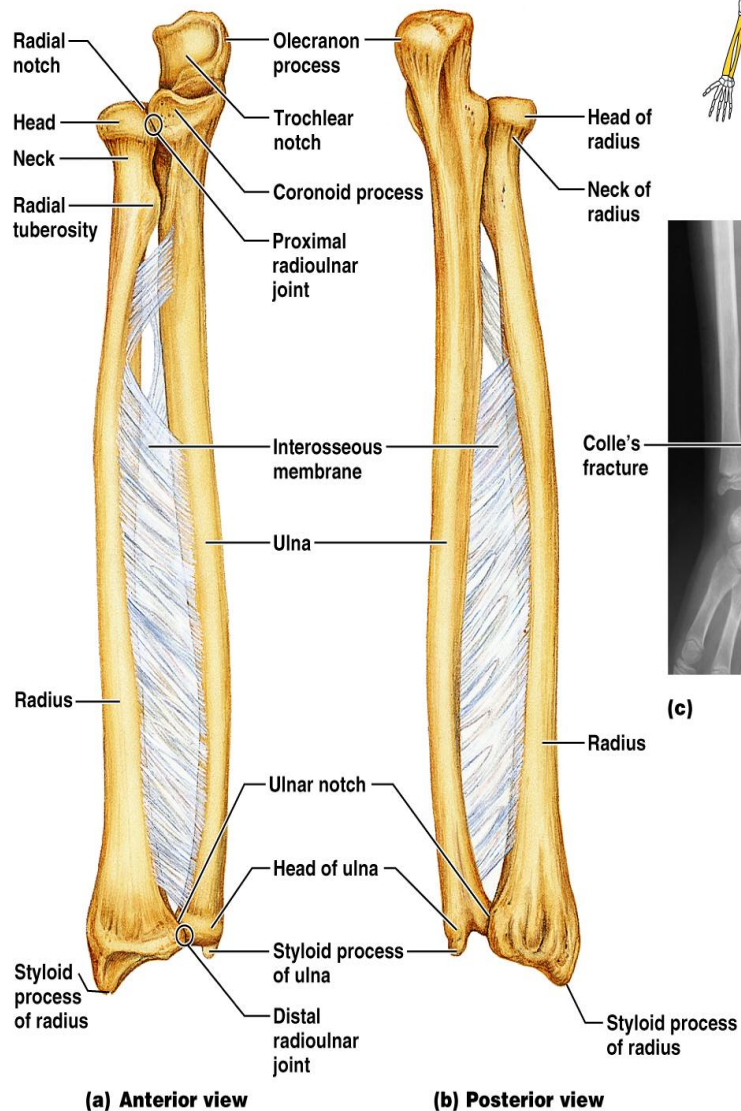
The Upper Limb

- The upper limb consists of the arm (brachium), forearm (antebrachium), and hand (manus)
- Thirty-seven bones form the skeletal framework of each upper limb
- The humerus is the sole bone of the arm
- It articulates with the scapula at the shoulder, and the radius and ulna at the elbow
- Major markings
 - Proximal humerus includes the head, anatomical and surgical necks, greater and lesser tubercles, and the intertubercular groove
 - Distal humerus includes the capitulum, trochlea, medial and lateral epicondyles, and the coronoid and olecranon fossae
 - Medial portion includes the radial groove and the deltoid process



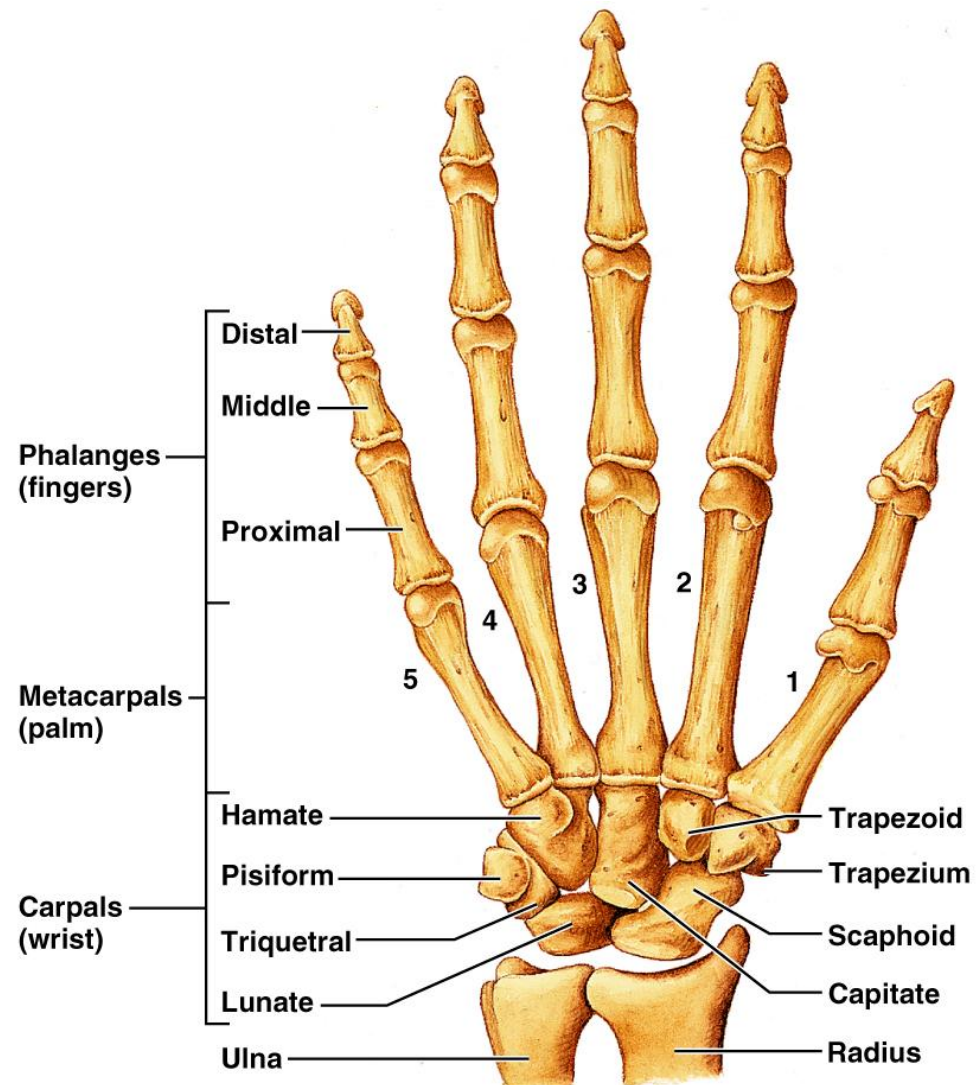
Forearm

- The bones of the forearm are the radius and ulna
- They articulate proximally with the humerus and distally with the wrist bones
- They also articulate with each other proximally and distally at small radioulnar joints
- Interosseous membrane connects the two bones along their entire length
- The ulna lies medially in the forearm and is slightly longer than the radius
 - Forms the major portion of the elbow joint with the humerus
 - Its major markings include the olecranon, coronoid process, trochlear notch, radial notch, and the styloid process
- The radius lies opposite (lateral to) the ulna and is thin at its proximal end, widened distally
 - The superior surface of the head articulates with the capitulum of the humerus
 - Medially, the head articulates with the radial notch of the ulna
 - Major markings include the radial tuberosity, ulnar notch, and styloid process



Hand

- Skeleton of the hand contains wrist bones (carpals), bones of the palm (metacarpals), and bones of the fingers (phalanges)
- Consists of eight bones
 - Scaphoid, lunate, triquetral, and pisiform proximally
 - Trapezium, trapezoid, capitate, and hamate distally
- Five numbered (1-5) metacarpal bones radiate from the wrist to form the palm
 - Their bases articulate with the carpals proximally, and with each other medially and laterally
 - Heads articulate with the phalanges
- Each hand contains 14 miniature long bones called phalanges
- Fingers (digits) are numbered 1-5, beginning with the thumb (pollex)
- Each finger (except the thumb) has three phalanges - distal, middle, and proximal
- The thumb has no middle phalanx

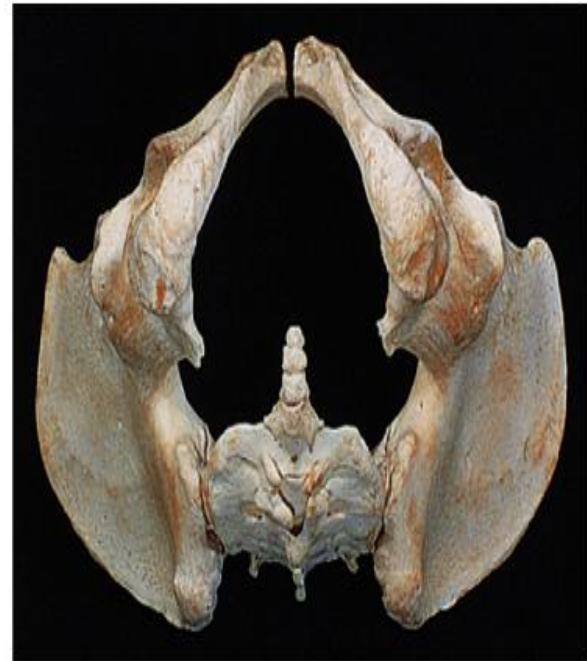
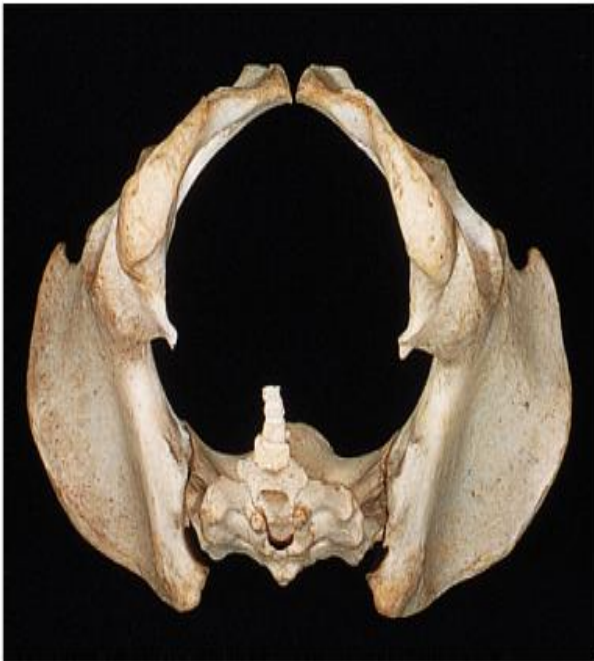
(a)

Figure 7.26a

Comparison of Male and Female Pelvic Structure

- Female pelvis
 - Tilted forward, adapted for childbearing
 - True pelvis defines birth canal
 - Cavity of the true pelvis is broad, shallow, and has greater capacity
- Male pelvis
 - Tilted less forward
 - Adapted for support of heavier male build and stronger muscles
 - Cavity of true pelvis is narrow and deep



Comparison of Male and Female Pelvic Structure

Characteristic	Female	Male
Bone thickness	Lighter, thinner, and smoother	Heavier, thicker, and more prominent markings
Pubic arch/angle	80°–90°	50°–60°
Acetabula	Small; farther apart	Large; closer together
Sacrum	Wider, shorter; sacral curvature is accentuated	Narrow, longer; sacral promontory more ventral
Coccyx	More movable; straighter	Less movable; curves ventrally

Comparison of Male and Female

TABLE 7.4 Comparison of the Male and Female Pelves

CHARACTERISTIC	FEMALE	MALE
----------------	--------	------

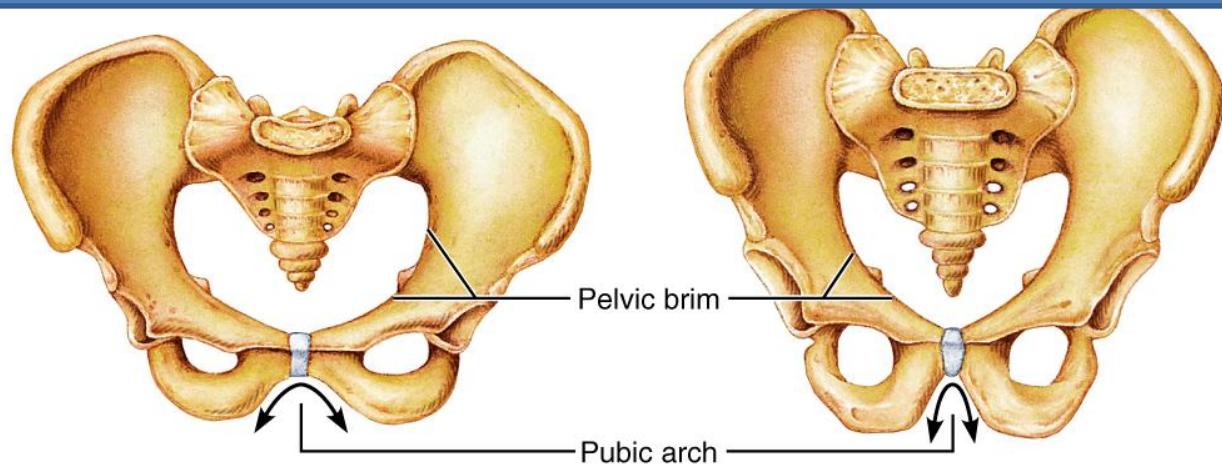
General structure and functional modifications

Bone thickness

Acetabula

Pubic arch/angle

Anterior view

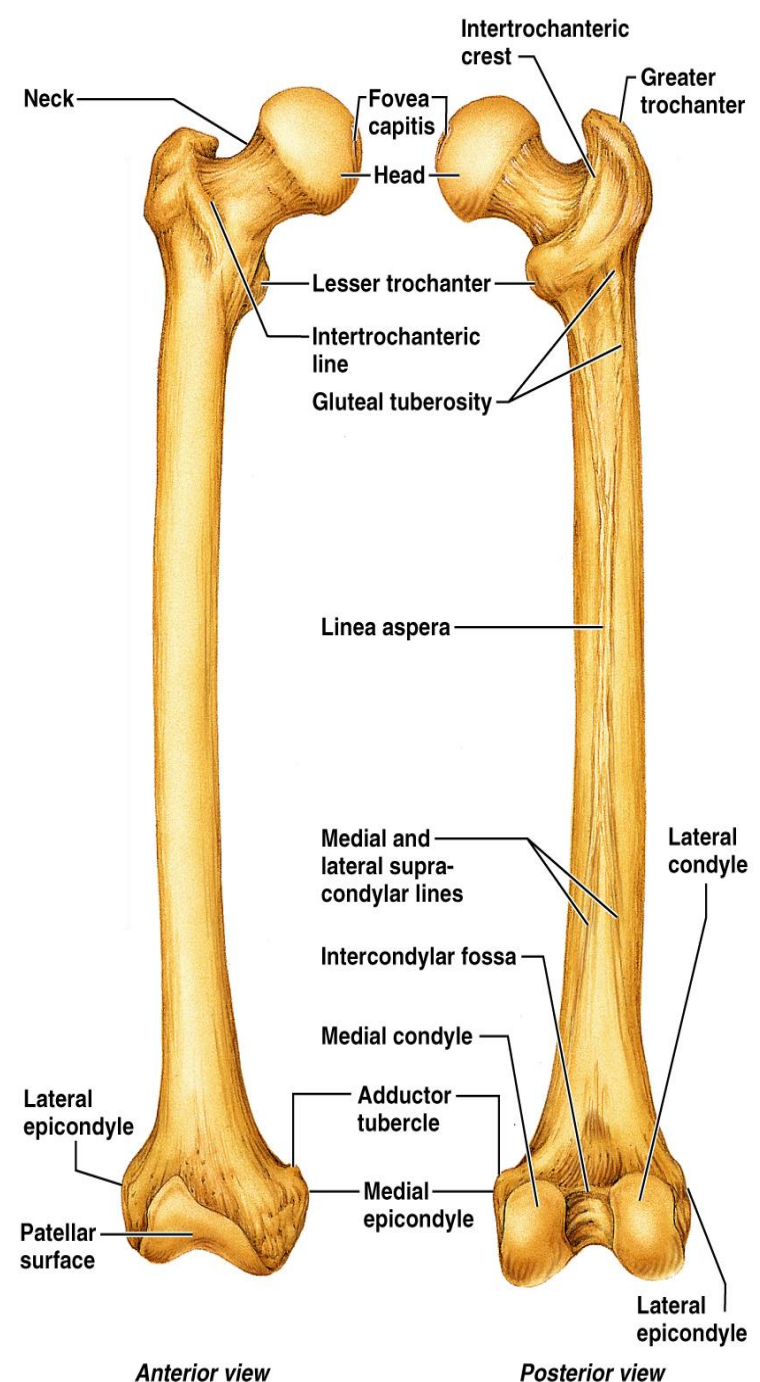
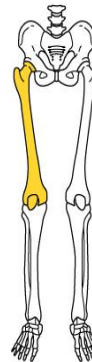

The Lower Limb

- The three segments of the lower limb are the thigh, leg, and foot
- They carry the weight of the erect body, and are subjected to exceptional forces when one jumps or runs
- The sole bone of the thigh is the femur, the largest and strongest bone in the body
 - It articulates proximally with the hip and distally with the tibia and fibula

Major markings include:

- lateral and medial condyles
- greater and lesser trochanters
- head
- patellar surface
- medial and lateral epicondyles



(b) Femur

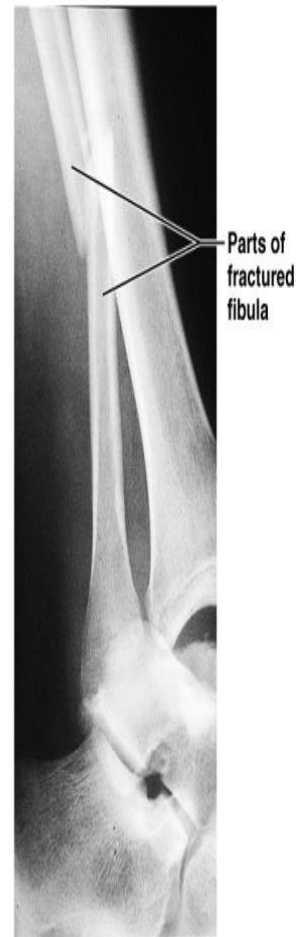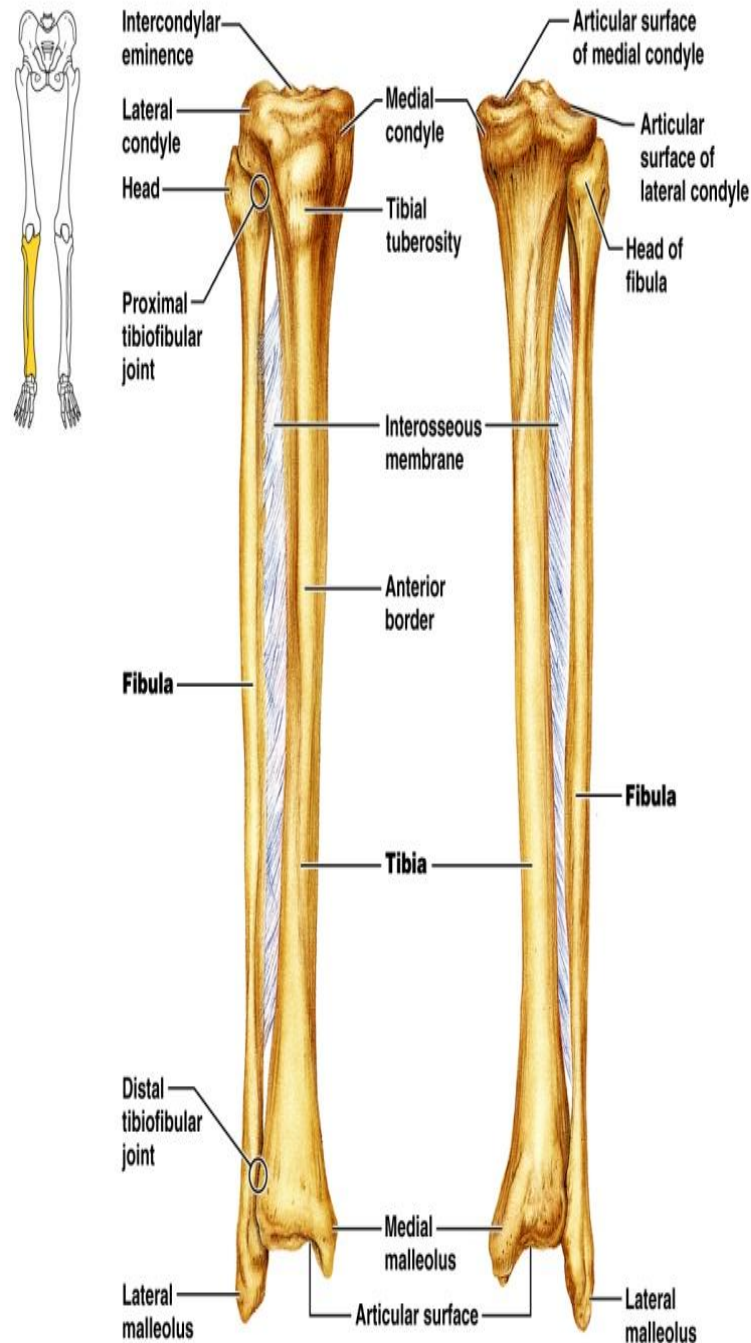
Tibia

Tibia

- Receives the weight of the body from the femur and transmits it to the foot
- Major markings include medial and lateral condyles, intercondylar eminence, the tibial tuberosity, anterior crest, medial malleolus, and fibular notch

Fibula

- Sticklike bone with slightly expanded ends located laterally to the tibia
- Major markings include the head and lateral malleolus



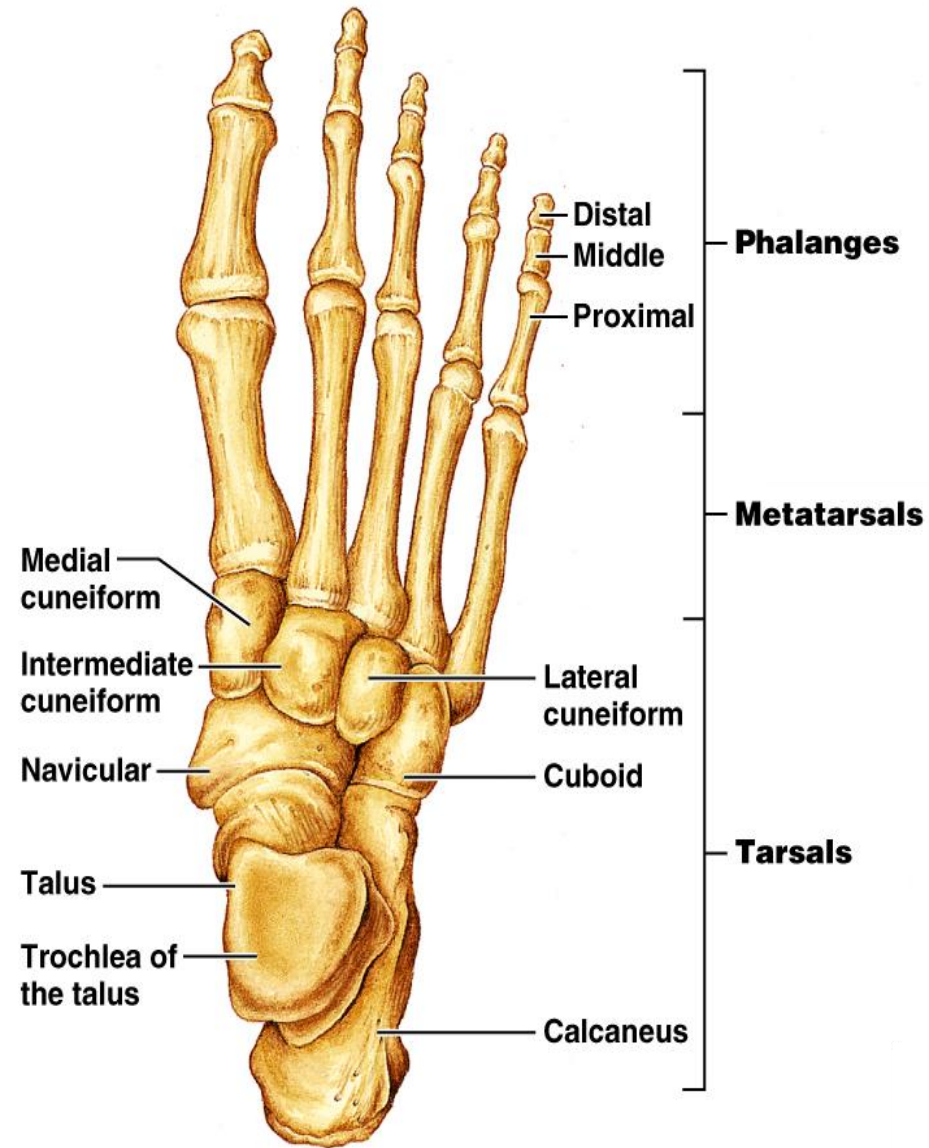
(c)

(a) Anterior view

(b) Posterior view

Foot

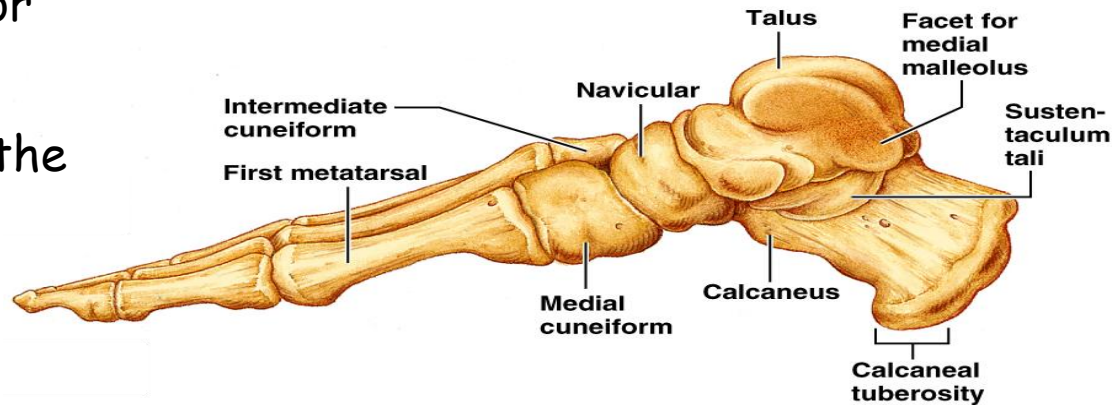
- The skeleton of the foot includes the tarsus, metatarsals, and the phalanges (toes)
- The foot supports body weight and acts as a lever to propel the body forward in walking and running
- Body weight is carried primarily on the talus and calcaneus
- Talus articulates with the tibia and fibula superiorly, and the calcaneus inferiorly
- Other tarsus bones include the cuboid and navicular, and the medial, intermediate, and lateral cuneiforms



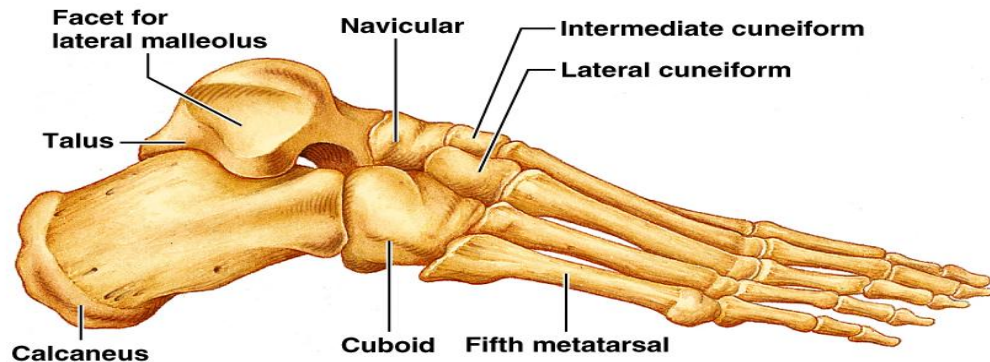
(a) Superior view

Calcaneus

- Forms the heel of the foot
- Carries the talus on its superior surface
- Point of attachment for the calcaneal (Achilles) tendon of the calf muscles
- Metatarsals
 - Five (1-5) long bones that articulate with the proximal phalanges
 - The enlarged head of metatarsal 1 forms the "ball of the foot"
- Phalanges
 - The 14 bones of the toes
 - Each digit has three phalanges except the hallux, which has no middle phalanx



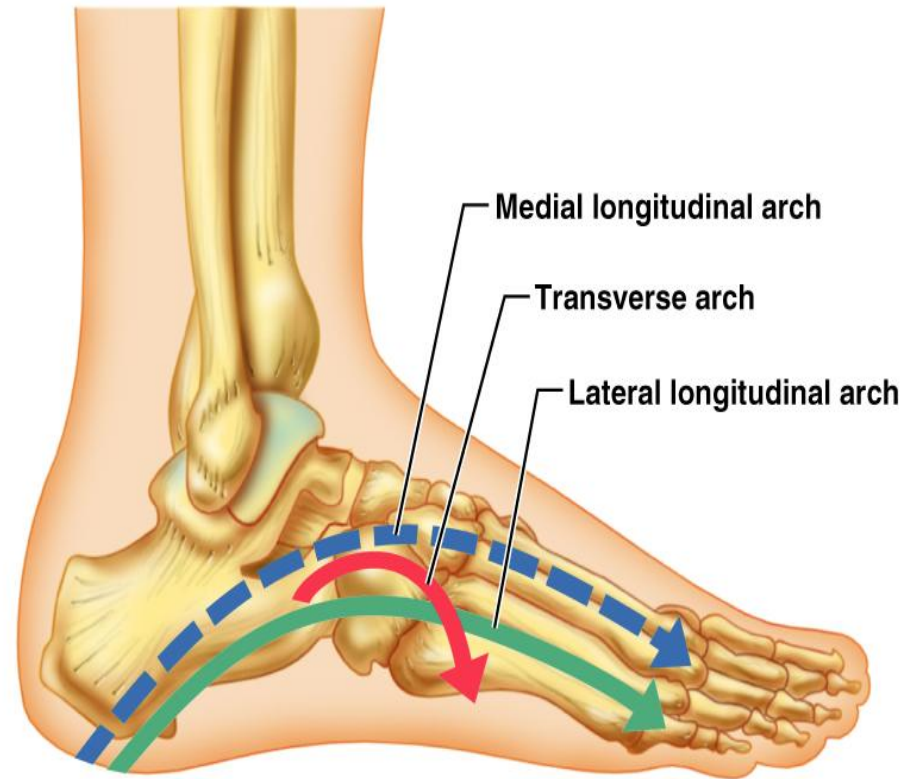
(b) Medial view



(c) Lateral view

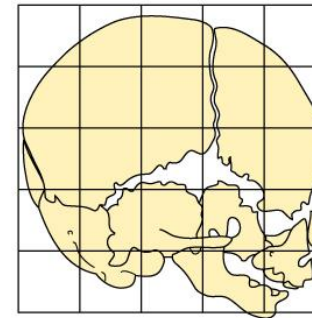
Arches of the Foot

- The foot has three arches maintained by interlocking foot bones and strong ligaments
- Arches allow the foot to hold up weight
- The arches are:
 - Lateral longitudinal - cuboid is keystone of this arch
 - Medial longitudinal - talus is keystone of this arch
 - Transverse - runs obliquely from one side of the foot to the other

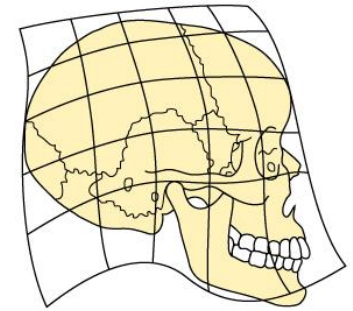


Development of Skeletal System

- At birth, the cranium is huge relative to the face
 - Mandible and maxilla are foreshortened but lengthen with age
- The arms and legs grow at a faster rate than the head and trunk, leading to adult proportions
- Only thoracic and sacral spinal curvatures are present at birth
 - The primary curvatures are convex posteriorly, causing the infant spine to arch like a four-legged animal
 - Secondary curvatures - cervical and lumbar - are convex anteriorly and are associated with the child's development
- Intervertebral discs become thin, less hydrated, and less elastic as we age
 - Risk of disc herniation increases
 - Loss of stature by several centimeters is common after age 55
 - Costal cartilages ossify causing the thorax to become rigid
 - All bones lose mass

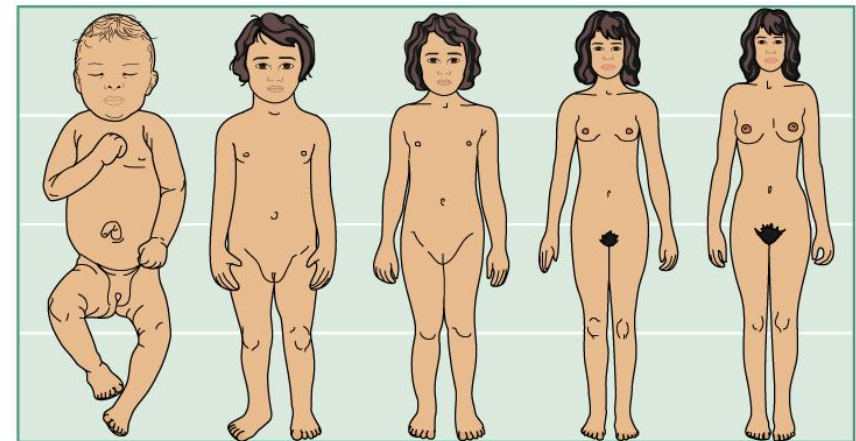


Human newborn



Human adult

(a)



Newborn

2 yrs.

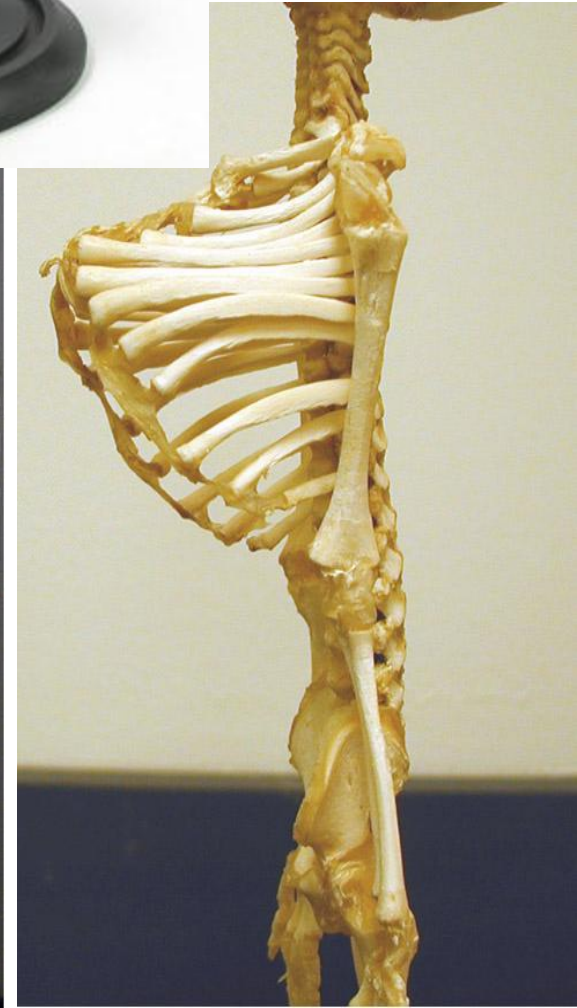
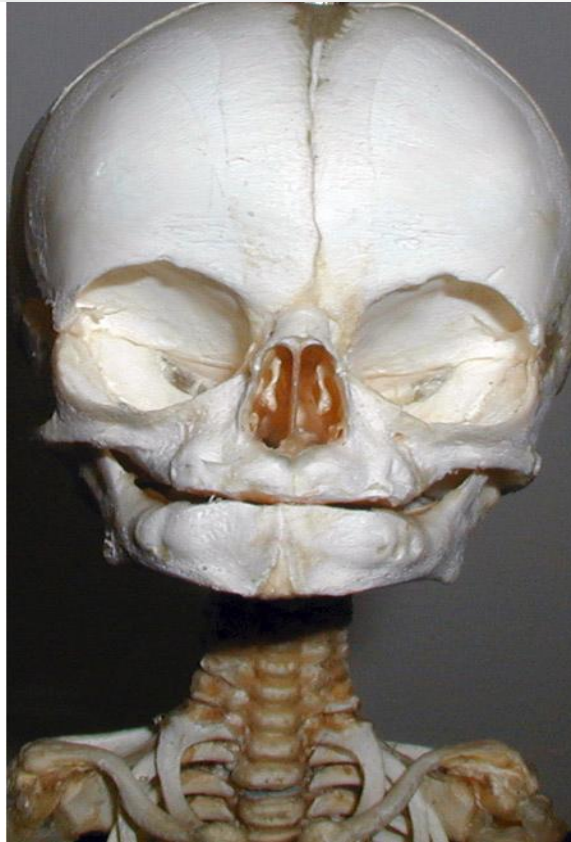
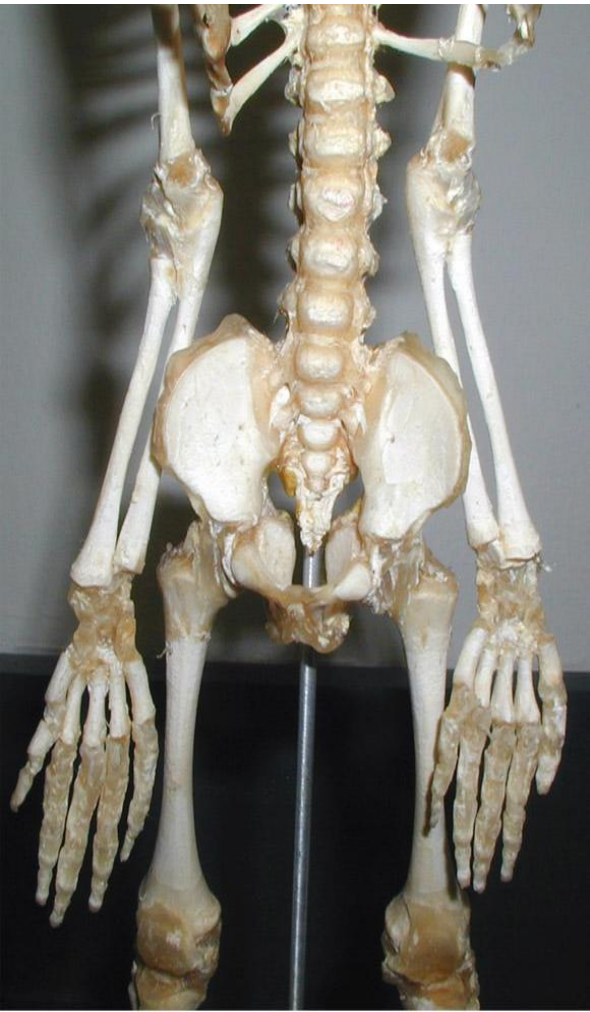5 yrs.

15 yrs.

Adult

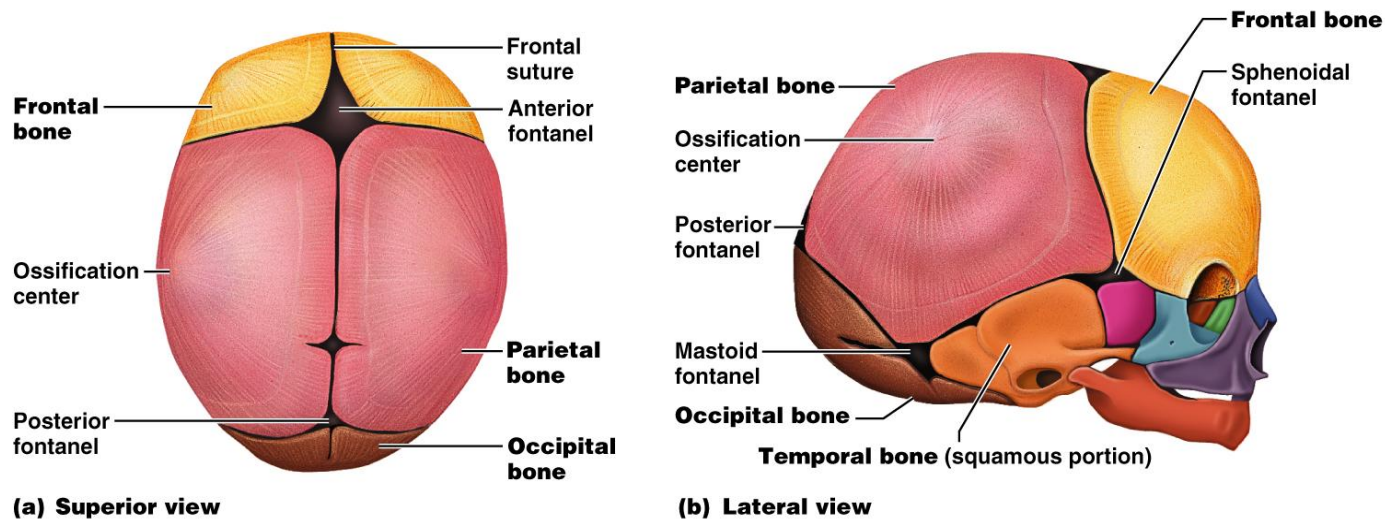
(b)

Human fetal skeleton



Developmental Aspects: Fetal Skull

- Infant skull has more bones than the adult skull
- At birth, fetal skull bones are incomplete and connected by fontanels
- Fontanels
 - Unossified remnants of fibrous membranes between fetal skull bones
 - The four fontanels are anterior, posterior, mastoid, and sphenoid



Fetal skull

4 Fontanelles

